

# PREDICTORS OF INTRAOCULAR PRESSURE AFTER PHACOEMULSIFICATION IN PRIMARY OPEN-ANGLE GLAUCOMA EYES WITH WIDE VERSUS NARROWER ANGLES (AN AMERICAN OPHTHALMOLOGICAL SOCIETY THESIS)

By Shan C. Lin MD, Marisse Masis MD, Travis C. Porco PhD MPH, and Louis R. Pasquale MD

## ABSTRACT

**Purpose:** To assess if narrower-angle status and anterior segment optical coherence tomography (AS-OCT) parameters can predict intraocular pressure (IOP) drop in primary open-angle glaucoma (POAG) patients after cataract surgery.

**Methods:** This was a prospective case series of consecutive cataract surgery patients with POAG and no peripheral anterior synechiae (PAS) using a standardized postoperative management protocol. Preoperatively, patients underwent gonioscopy and AS-OCT. The same glaucoma medication regimen was resumed by 1 month. Potential predictors of IOP reduction included narrower-angle status by gonioscopy and angle-opening distance (AOD500) as well as other AS-OCT parameters. Mixed-effects regression adjusted for use of both eyes and other potential confounders.

**Results:** We enrolled 66 eyes of 40 glaucoma patients. The IOP reduction at 1 year was  $4.2 \pm 3$  mm Hg (26%,  $P < .001$ ) in the narrower-angle group vs  $2.2 \pm 3$  mm Hg (14%,  $P < .001$ ) in the wide-angle group ( $P = .027$  for difference), as classified by gonioscopy. By AOD500 classification, the narrower-angle group had  $3.4 \pm 3$  mm Hg (21%,  $P < .001$ ) reduction vs  $2.5 \pm 3$  mm Hg (16%,  $P < .001$ ) in the wide-angle group ( $P = .031$  for difference). When the entire cohort was assessed, iris thickness, iris area, and lens vault were correlated with increasing IOP reduction at 1 year ( $P < .05$  for all).

**Conclusions:** In POAG eyes, cataract surgery lowered IOP to a greater degree in the narrower-angle group than in the wide-angle group, and parameters relating to iris thickness and area, as well as lens vault, were correlated with IOP reduction. These findings can guide ophthalmologists in their selection of cataract surgery as a potential management option.

*Trans Am Ophthalmol Soc 2017;115:T6[1-13]. ©2017 by the American Ophthalmological Society.*

## INTRODUCTION

A potential avenue for lowering intraocular pressure (IOP) in glaucoma patients is to perform phacoemulsification cataract surgery (Phaco). Numerous studies—most retrospective—have demonstrated that IOP is significantly reduced after Phaco (Table 1).<sup>1-34</sup>

The effect is typically mild in those eyes without glaucoma and appears to be greater in eyes with glaucoma and ocular hypertension. Eyes with exfoliation syndrome have an even more pronounced response to Phaco.<sup>17,23</sup> The greatest effect appears to be in eyes that have primary angle-closure glaucoma (PACG)<sup>5,21</sup>—both acute and chronic—in which IOP and medication reductions are typically substantial.<sup>21,27-29</sup>

**TABLE 1. EFFECT OF PHACOEMULSIFICATION ON INTRAOCULAR PRESSURE IN SELECTED PUBLISHED STUDIES IN THE PEER-REVIEWED LITERATURE**

AUTHOR	YEAR	TYPE OF GLAUCOMA	ABSOLUTE IOP DROP (MM HG)*
Samuelson <sup>57</sup>	2011	POAG/pigmentary/XFG	8.5
Mathalone <sup>3</sup>	2005	POAG	1.9
Damji <sup>17</sup>	2006	POAG/XFG	3.15
Shoji <sup>11</sup>	2007	NTG	5.1
Slabaugh <sup>6</sup>	2014	POAG	1.79
Iancu <sup>22</sup>	2014	POAG	1.9
Shingleton <sup>4</sup>	2006	POAG	1.4
Mierzejewsky <sup>23</sup>	2008	POAG/XFG	4.8/3.3
Hayashi <sup>24</sup>	2001	POAG/PACG	5.3/7.2
Tham <sup>27</sup>	2013	PACG	8.4
Shams <sup>25</sup>	2012	PAC/PACG	2.5
Moghimi <sup>26</sup>	2015	PACG	8.3
Azuara-Blanco <sup>21</sup>	2016	PAC/PACG	12.9
Liu <sup>84</sup>	2011	PACG	2.9

IOP, intraocular pressure; NTG, normal-tension glaucoma; PAC, primary angle closure; PACG, primary angle-closure glaucoma; POAG, primary open-angle glaucoma; XFG, exfoliation glaucoma.

\*IOP reported at the end of follow-up (average between 24 and 36 months).

From the Koret Vision Center, Department of Ophthalmology (Dr Lin, Dr Masis, Dr Porco), and the Proctor Foundation (Dr Porco), University of California, San Francisco Medical School, San Francisco, California; and the Massachusetts Eye and Ear Infirmary (Dr Pasquale) and the Channing Division of Network Medicine, Brigham and Women's Hospital (Dr Pasquale), Harvard Medical School, Boston, Massachusetts. Corresponding Author: Shan Lin, MD Email: Shan.Lin@ucsf.edu

Although the utility of performing Phaco alone in PACG is well recognized and the evidence has advanced to the point that early cataract surgery is considered a viable alternative to managing IOP elevation,<sup>21</sup> the data for the IOP lowering in cases of primary open-angle glaucoma (POAG) is less rigorous and compelling. As a result, the performance of Phaco without an adjunctive glaucoma procedure for POAG is more controversial.

It is felt by many investigators that the IOP lowering in POAG is not significant, whereas others believe that it is substantial enough to be a criterion for whether to do Phaco—and possibly early Phaco—in a patient with coexistent diseases.<sup>1-4,6</sup> In developing countries where cataract surgery is an option but glaucoma medication use or glaucoma surgery or both are not readily available, the clarification of the effectiveness of Phaco (or even manual cataract extraction) as a stand-alone surgical treatment for the glaucoma aspect is particularly important. Specifically, if there are significant predictors for the IOP lowering, they would be especially useful to the clinician in a limited resources setting and even for ophthalmologists in the United States, where cost containment and cost-effectiveness and safety in health care are increasingly scrutinized.

In POAG and ocular hypertension cases, the most consistent predictor of IOP lowering after Phaco has been the preoperative IOP, with higher IOP correlated with greater reduction.<sup>6,30</sup> Anterior chamber depth has also been investigated as a potential predictor and has been found to be associated in some studies<sup>33,34</sup> but not in others.<sup>8,31</sup>

Another potential anatomic predictor may be the anterior chamber angle width. This factor may be assessed clinically by gonioscopy or by anterior segment imaging. Anterior segment optical coherence tomography (AS-OCT) is a particularly useful imaging modality because it is high-resolution, noncontact, and rapid. Furthermore, software currently exists to assess the anterior chamber angle as well as other anterior chamber parameters using this technology.<sup>31,32,35-37</sup>

AS-OCT was first described in the literature for clinical use by Radhakrishnan and colleagues.<sup>38</sup> This technology provides an objective method to assess the anterior segment of the eye, including the anatomy of the anterior chamber angle. It allows both qualitative and quantitative analyses of the angle and has shown excellent potential for studying the pathophysiology of different types of glaucoma, particularly those in the spectrum of angle closure.<sup>38-40</sup> AS-OCT uses the principle of low coherence interferometry to produce cross-sectional images of the anterior segment; it measures the delay and intensity of the light reflected from the tissue structure and compares it with the reflected light by a reference mirror.<sup>41</sup> With use of customized software, AS-OCT images can be analyzed to obtain measures of anterior chamber depth, anterior chamber area, anterior chamber width, lens vault, iris thickness, iris area, iris curvature, and anterior chamber angle measures such as angle-opening distance (AOD), angle recess area, and trabecular-iris space area.<sup>42-44</sup> Studies have shown that reproducibility using this software is excellent.<sup>45,46</sup>

It could be argued that objective imaging of the angle provides more anatomically correct information about the anterior chamber angle than traditional gonioscopy. The reproducibility of gonioscopy between different clinicians is poor.<sup>45</sup> However, dynamic gonioscopy affords the clinician the ability to distinguish true peripheral anterior synechiae (PAS) vs iridotrabecular contact that is not chronic angle closure. In relation to angle closure, the main benefit of AS-OCT may be in the detection of potential closure when gonioscopy is not typically performed, or as a way to double-check even when gonioscopy is done. Most typically, inadvertent dynamic gonioscopy leads to an assessment of open angle when the subject actually has narrow or occludable angles. In a study published in 2010, it was found that Visante OCT (Carl Zeiss Meditec Inc) is capable of detecting closed angles, even in areas assessed as open on gonioscopy; 49% of the eyes described as open angle on gonioscopy were reported to have at least one quadrant closed by OCT.<sup>47</sup>

AS-OCT has also been a tremendous tool for the study of the anatomic mechanisms associated with glaucoma, mostly for angle-closure disease. Mechanisms involved in IOP elevation and glaucoma pathophysiology, and the relationship with anterior segment anatomy, remain to be fully elucidated. There have been several theories related to the mechanisms for glaucoma development, but there is increasing evidence that glaucoma is not caused by a single mechanism and that there are several factors, including the anatomy of the anterior chamber, that can influence the dynamics of aqueous humor outflow, again mainly in eyes with PACG and suspected angle closure.<sup>48,49</sup>

In a recent study, Nongpiur and colleagues<sup>50</sup> highlighted the potential of lens vault, anterior chamber depth, and anterior chamber width to be key parameters in a pathophysiology-orientated approach to determining PACG and narrow-angle classification.

In addition to being a major tool for the diagnosis of angle closure and for the study of the mechanisms responsible for it, AS-OCT may have an important role in Phaco as a clinical utility both for the prediction of IOP reduction and in the elucidation of how Phaco may lower eye pressure. Yang and colleagues<sup>51</sup> demonstrated that IOP reduction was proportional to the increase in AOD after cataract surgery in normal eyes without glaucoma, suggesting that the angle change is a mechanism by which the IOP is decreased. Another report<sup>31</sup> also showed that preoperative AOD (in univariate analysis) and AOD change (in multivariate analysis) and other parameters from AS-OCT predicted the IOP drop in nonglaucomatous eyes. However, these studies and others related to angle and anterior chamber anatomy<sup>31,32,51</sup> were conducted in subjects without glaucoma; the more clinically relevant population are those glaucoma patients who may benefit from better IOP control.

In the present prospective study, we have assessed the relationship of the angle status to IOP reduction after Phaco in eyes with POAG on a spectrum from narrower angles (without PAS) to wide-open angles. We have evaluated angle classification by both clinical gonioscopy and a representative anterior chamber angle parameter (AOD) from AS-OCT as potential predictive factors of IOP at 1 year. In addition, we looked at common anterior segment parameters from AS-OCT, which may also be predictors of IOP reduction. On the basis of prior studies in subjects without glaucoma, we hypothesize that narrower-angle status will predict greater IOP lowering and that some AS-OCT parameters, such as lens vault, will be predictive as well.

Although numerous prior studies have reported the association of anterior segment measures with IOP results after Phaco, they

have been in patients without glaucoma. This is the first prospective study to evaluate the predictive value of gonioscopy and AS-OCT status for IOP reduction after Phaco in patients with POAG. Another unique aspect of the present study is the maintenance of the same glaucoma medication regimen before and after the Phaco surgery, whereas other studies on glaucoma patients have allowed for adjustment of glaucoma medications after Phaco, typically to fewer medications, since the IOP has improved. Thus, we have been able to isolate the true IOP effect of Phaco without adjustment for change in glaucoma drug regimen.

## METHODS

In this prospective, observational study we recruited consecutive glaucoma patients attending the Glaucoma Service at the University of California, San Francisco, who were scheduled for Phaco with posterior chamber IOL placement, between June 1, 2009, and November 30, 2016. Informed written consent was obtained from all enrollees. All procedures adhered to the tenets of the Declaration of Helsinki, and data collection adhered to the Health Insurance Portability and Accountability Act (HIPAA) of 1996. Our study was approved by the Committee on Human Research at the University of California, San Francisco (No. 14-14328).

### PATIENT CRITERIA AND GLAUCOMA DEFINITIONS

This study enrolled patients who had a diagnosis of glaucoma based on the International Society of Geographical and Epidemiological Ophthalmology (ISGEO) criteria noted here, without evidence of secondary causes such as exfoliation syndrome, and were stratified based on angle configuration as described below. The inclusion criteria for all eligible patients were (1) age >18 years; (2) presence of a visually significant cataract that caused significant limitation in general function, glare, or other visual limitation; (3) diagnosis of glaucoma as defined below; and (4) willingness and ability to perform all testing required in the study. Exclusion criteria included (1) history of prior intraocular surgery such as trabeculectomy or tube surgery; (2) PAS; (3) history of eye trauma, uveitis, substantial retinal disease such as wet macular degeneration, or congenital anomalies; (4) pigmentary dispersion syndrome, exfoliation syndrome, or other secondary cause of glaucoma; and (5) physical inability to perform tests in the study.

We included eyes that had undergone laser peripheral iridotomy but excluded those that had prior laser trabeculoplasty. The reason for inclusion of eyes that had undergone laser peripheral iridotomy is that these eyes received laser for occludable angles but do not have chronic closure (specifically, PAS) and most often have an open angle at the time of cataract surgery. We also included both eyes of patients into the study if they met the inclusion and exclusion criteria. Mixed-effects regression was performed to account for the use of both eyes.

Eyes were classified and included as having glaucoma if they met the following criteria based on the ISGEO guidelines<sup>52</sup>:

Category 1: a visual field defect that is consistent with glaucomatous optic neuropathy, and either a vertical cup-disc ratio (VCDR) of at least 0.7 (97.5th percentile) or VCDR asymmetry between the right and left eyes of at least 0.2 (97.5th percentile);

Category 2: visual field results are not definitive or are unattainable due to patient inability to perform an adequate quality test, and optic disc has VCDR of at least 0.9 (99.5th percentile) or VCDR asymmetry between the right and left eyes of at least 0.3 (99.5th percentile); or

Category 3: visual field testing and optic disc examination are not possible in the subject, and visual acuity is less than 20/400 (for any ophthalmic pathology) and IOP exceeds 21 mm Hg (99.5th percentile for the population).

Visual field testing was performed with the Humphrey Field Analyzer (HFA2; Carl Zeiss Meditec, Inc) using the Swedish Interactive Thresholding Algorithm (SITA) 24-2 protocol. Glaucomatous fields were defined by Glaucoma Hemifield Test results that were outside of normal limits and/or the corrected pattern standard deviation was  $P < 5\%$ . A visual field was considered reliable if fixation losses, false-positives, and false-negatives were  $< 20\%$ .

Testing was repeated at least once if the initial field was not reliable. If multiple visual field tests were unsuccessful in achieving a reliable result, then subjects were considered for glaucoma diagnosis using the ISGEO category 2 or category 3 criteria. However, none of the subjects enrolled in this study were enrolled on the basis of category 2 or 3 criteria. All subjects met the category 1 criteria.

The Shaffer classification system was used in this study for grading of the angle. Briefly, grade levels were divided as follows: (1) Grade 0 was 0° angle configuration; (2) Grade 1 was greater than 0° and less than 15°; (3) Grade 2 was greater than 15° and less than 25°; (4) Grade 3 was greater than 25° and less than 35°; and (5) Grade 4 was 35° or greater. Peripheral anterior synechia were detected by performing dynamic gonioscopy using the Posner gonioscopy lens.

Glaucoma eyes included in this study met the following glaucoma criteria for inclusion: (1) glaucoma diagnosis as defined by the ISGEO criteria described above; (2) absence of other causes of glaucoma, such as pseudoexfoliation and pigment dispersion; and (3) absence of PAS on gonioscopy. Eyes were further subdivided into narrow without PAS (henceforth denoted as “narrower angle”) eyes and wide open (further denoted as “wide angle”) eyes. Narrower-angle eyes were defined as those with three or four quadrants with grade 2 or less but without PAS on dynamic gonioscopy. Wide-angle eyes were those with grade 3 or greater in two or more quadrants; the other quadrants could be grade 2 but not grade 0 or 1 or possess PAS. We also divided the eyes into narrower-angle and wide-angle eyes based on AS-OCT criteria, which is further described below.

All glaucoma patients were taking glaucoma medications prior to cataract surgery. The same glaucoma medications were resumed the day after surgery, except for prostaglandin analogs. After 1 month, the same prostaglandin analogs were resumed and study eyes were then back on the same glaucoma medication regimen. The study was designed in this way to isolate the outcome variable as the IOP change without any confounding effect from medication changes after the surgery. As a safety measure, study protocol was suspended if persistent IOP less than 5 mm Hg was encountered.

## DEMOGRAPHIC AND CLINICAL DATA COLLECTED

We collected demographic and clinical information, including age, gender, race/ethnicity, medical and surgical history, medications, allergies, and family history of ocular disease, through medical chart review and direct interview of the patients.

All enrolled subjects received a slit-lamp examination (Model 900; Haag-Streit, Inc) of the anterior segment and dilated fundus examination. Tonometry and gonioscopy were performed prior to dilation. Goldmann applanation tonometry was conducted by a single ophthalmologist with the assistance of a coordinator who turned the dial of the device until the semicircles were ascertained by the ophthalmologist to be in the correct position. Two measurements were obtained, and a third was obtained if the two values differed by more than 2 mm Hg. In the latter situation, the median value was used. Otherwise, the average of the two values was used for analysis. Intraocular pressure was taken between 2 and 4 PM at all study visits to minimize the effects of diurnal variation. Gonioscopy was performed using a Posner-style 4-mirror gonioscopy lens (model OPDSG; Ocular Instruments, Inc). A single glaucoma fellowship-trained ophthalmologist (S.C.L.) conducted gonioscopy at 16× magnification with slit-lamp biomicroscopy in a darkroom setting. All four quadrants (superior, nasal, temporal, and inferior) were graded according to the Shaffer classification (described above).

Ocular biometry was performed using the IOL Master (Carl Zeiss Meditec, Inc) or LENSTAR LS 900 (Haag-Streit, Inc), and we recorded axial length and anterior chamber depth. (However, anterior chamber depths for analyses in this study were obtained from semi-automated calculations with the AS-OCT images). Central corneal thickness was obtained from ultrasound pachymetry (DGH-500 or DGH-550 Pachette; DGH Technology Inc).

## CATARACT SURGICAL PROCEDURE AND POSTOPERATIVE CARE

Cataract surgery by Phaco was performed by one of the authors (S.C.L.); all patients were under topical or sub-Tenon's anesthesia. Briefly, after anesthesia was induced, a 2.8-mm temporal incision was created in the clear cornea using a diamond knife; a cystitome and Utrata forceps were used to create an approximately 5.5-mm-diameter anterior capsulorhexis. Hydrodissection and hydrodelineation were carried out with a Chang cannula. The lens nucleus was removed utilizing the “stop and chop” technique (Infiniti or Centurion; Alcon Laboratories, Inc); the epinucleus was then removed using the “epinucleus” mode with less phaco energy and slower aspiration rate. The cortex was removed with the irrigation/aspiration handpiece and the “cortex” mode on the device. After the lens bag and anterior chamber were filled with viscoelastic agent, a one-piece acrylic intraocular lens (AcrySof SA60AT or AcrySof IQ SN60WF; Alcon Laboratories, Inc) was placed in the bag. Then the viscoelastic material was removed using the “Visco” setting and the irrigation/aspiration handpiece, and the wound was tested for any leakage. Antibiotic prophylaxis was provided as a subconjunctival or intraocular injection.

Postoperative therapy included topical antibiotics four times a day for 1 week and topical prednisolone acetate (1%) initiated at four times a day and tapered over 4 weeks. Postoperative checkups were conducted at 1 day, 1 week, 1 month, 4 months, 7 months, and 1 year after surgery. At each visit, we tested visual acuity and IOP and performed a slit-lamp examination. At the 1-month visit, the eye was dilated and a complete fundus examination was conducted to look for any cystoid macular edema, retinal detachment, or other retinal pathology.

## ANTERIOR SEGMENT OPTICAL COHERENCE TOMOGRAPHY PROCEDURE AND IMAGE ANALYSIS

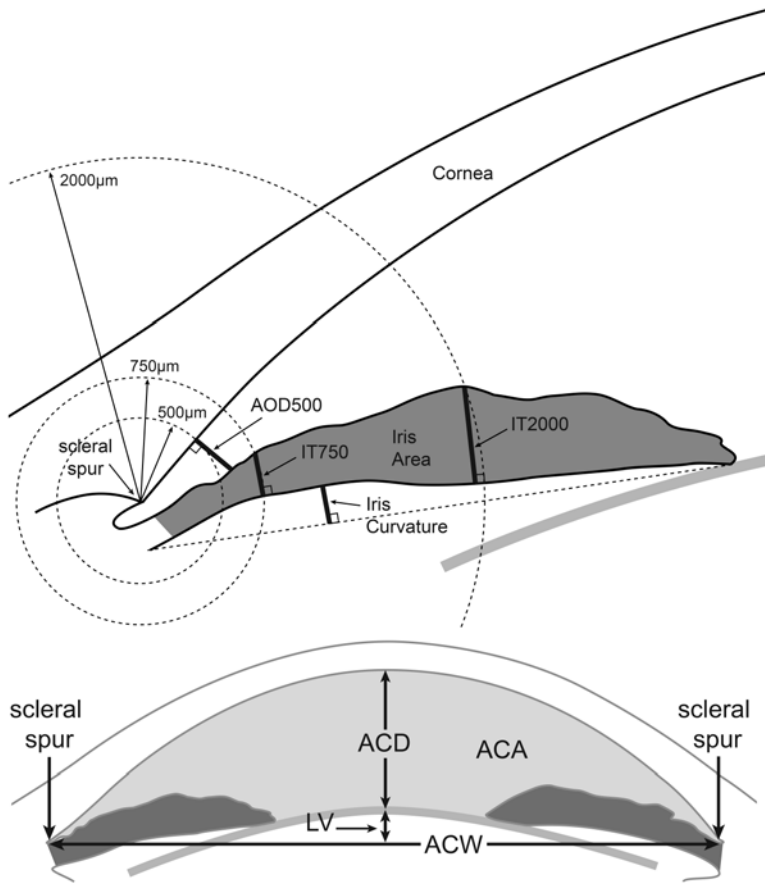
AS-OCT images were captured using the Visante OCT (Carl Zeiss Meditec, Inc) by trained researchers who were masked to the clinical data. Imaging was performed 1 week prior to surgery and then repeated using the same protocol 1 year after surgery. Images were obtained under dark conditions (0 lux using the Extech EasyView digital light meter, Model EA30; Extech Instruments, Inc) with the patient in the sitting position. Images were oriented in the horizontal (0-180°) meridians and imaged in the “single anterior segment” imaging mode. Eyes were oriented to fixate centrally in order to optimize the central corneal reflection. Images were selected according to the quality of the corneal reflection, the visibility of the scleral spurs, and the clarity and continuity of the anterior segment structures. Three images were taken, and the image judged to have the best quality by the above criteria was selected.

AS-OCT images were quantitatively assessed using the Zhongshan Angle Assessment Program (ZAAP, Guangzhou, China). For the angle and iris parameters, data from the nasal angles were utilized in this study, since the temporal angles could be affected by the surgical site being at or adjacent to the scan area, thus affecting the comparative analysis of preoperative vs postoperative images. Although the present study focuses only on the preoperative factors, later analyses and studies will delineate the results of angle and iris change. Thus, to maintain consistency, we have chosen to analyze the nasal portion for these parameters. Anterior segment parameters such as anterior chamber area and volume include both temporal and nasal sides.

Parameters related to the angle and anterior segment have been previously described (Figures 1 and 2).<sup>35-37,53-55</sup> To evaluate the role of the angle, we utilized AOD500 (defined below and commonly used to represent the anterior chamber angle width) to divide eyes into narrow angles vs open angles with a cutoff of 200 μm (median in our pilot study cohort). Other parameters that we analyzed in this study were iris thickness, iris area, iris curvature, lens vault, anterior chamber depth, anterior chamber width, anterior chamber area, and anterior chamber volume.

*Angle-opening distance* is defined as the length of the perpendicular line between the cornea-trabecular meshwork (500 or 750 μm anterior to the scleral spur) and the anterior iris surface. The iris thicknesses 750 and 2000 (IT750 and IT2000, respectively) represent the *iris thickness* measured at the iris surface starting from 750 and 2000 μm from the scleral spur, respectively. *Iris curvature* is defined as the length of a perpendicular line joining the point of greatest convexity along the posterior iris to the line that extends from the most peripheral to the most central points along the posterior iris surface. *Iris area* is defined as the area across the full length of the iris measured in square millimeters with the patient seated under 0 lux ambient lighting conditions. *Lens vault* is defined as the

length of a perpendicular line between the anterior pole of the phakic lens and the line between the two scleral spurs in microns. The *anterior chamber area* is defined as the area ( $\text{mm}^2$ ) contained within the corneal endothelium, anterior iris surface, and anterior lens surface (within the pupil). *Anterior chamber width* is represented by the line between the scleral spurs taken in the 0 to 180° meridian.



**FIGURE 1**

Anatomical parameters of the anterior chamber angle derived from assessment of anterior segment optical coherence tomography (AS-OCT). Angle-opening distance 500 (AOD500) is defined as the length of the perpendicular line between the cornea-trabecular meshwork (500  $\mu\text{m}$  anterior to the scleral spur) and the iris surface. The iris thicknesses 750 (IT750) and 2000 (IT2000) represent the iris thickness measured at the iris surface 750 and 2000  $\mu\text{m}$  from the scleral spur, respectively. Iris curvature is defined as the perpendicular line joining the point of greatest convexity along the posterior iris to the line that extends from the most peripheral to the most central points along the posterior iris surface. Iris area is defined as the area across the full length of the iris.

**FIGURE 2**

Anatomical parameters of the anterior chamber derived from assessment of anterior segment optical coherence tomography (AS-OCT). Lens vault (LV) is defined as the perpendicular line between the anterior pole of the phakic lens and the line between the two scleral spurs. The anterior chamber area (ACA) is defined as the area contained within the corneal endothelium, anterior iris surface, and anterior lens surface (within the pupil). Anterior chamber width (ACW) is represented by the line between the scleral spurs. Anterior chamber depth (ACD) is the depth of the anterior chamber from the central point of the cornea endothelium to the anterior pole of the lens.

## MAIN PREDICTORS OF INTRAOCULAR PRESSURE CHANGE AFTER PHACOEMULSIFICATION CATARACT SURGERY

The main predictor in this study was narrower vs wide angle status. Division of the angle status was by (1) gonioscopy grading and (2) AS-OCT imaging using AOD500 as the key parameter. The cutoff for AOD500 was the median value obtained from our pilot study of glaucoma subjects who received cataract surgery (200  $\mu\text{m}$ ). The distinction between narrower vs wide by gonioscopy was described above. Additional potential predictors that were evaluated included AS-OCT parameters described above (IT750, IT2000, iris curvature, iris area, lens vault, anterior chamber depth, anterior chamber width, anterior chamber area).

## MAIN OUTCOMES

The main outcome of this study was IOP change at 1 year after Phaco. Intraocular pressure was evaluated as absolute change in mm Hg.

### Statistical Analysis

Data was analyzed using Stata software (version 14; StataCorp LP) and R version 2.10 (R Foundation for Statistical Computing, <http://www.r-project.org>). Continuous variables were reported as mean  $\pm$  SD, and the Student *t* test was used to assess differences between paired continuous variables. For categorical variables we used the chi-square test to calculate differences between groups. We utilized linear mixed-effects regression analysis to determine the correlation between the outcome variable and preoperative

factors, including preoperative IOP, age, gender, central corneal thickness, and AS-OCT parameters, in both univariate and multivariate analysis. The mixed-effects model was performed to adjust for the use of both eyes in some subjects.

Statistically, the outcome was set as the IOP before surgery minus the IOP after surgery at 1 year ( $IOP_{preop} - IOP_{postop}$ ). For the analysis of AS-OCT parameters as possible predictors among the entire group, individual parameters were placed in the model separately to test their respective association with the outcome, adjusting for preoperative IOP, age, gender, and central corneal thickness. We did not include all the parameters into the model, since many of the factors are colinear. For example, anterior chamber depth and anterior chamber area would be colinear and their individual significance would be cancelled out by inclusion of both into the model. We utilized the robust estimation of linear mixed-effects models (R version 2.10) to determine correlations, *P* values, and 95% CIs. Statistical significance was set at a *P*<.05.

**Reproducibility of the AS-OCT Measurements**

To test the reproducibility of our AS-OCT measurements, we randomly selected 10 images to retest the values achieved with manually identifying the scleral spurs. The same grader was masked to prior results and clinical data when manually identifying the scleral spurs. For this study, reproducibility of AS-OCT measurements is described as intraclass correlation coefficient (ICC) using a 1-way random-effects model based on AOD500 measurements.

**RESULTS**

We enrolled 66 eyes from 40 patients with glaucoma. The mean age of all participants was 77±7 years, and gender distribution was 41% female. Table 2 shows the demographic data of the enrollees.

**TABLE 2. BASELINE CHARACTERISTICS OF THE STUDY POPULATION**

VARIABLE	TOTAL	NARROWER ANGLE*	WIDE ANGLE*
Eyes, n (%)	66 (100)	27 (41)	39 (59)
Mean age ± SD, yr	77 ± 7	76.5±8	78.1±7
Gender female, n (%)	36 (55)	19 (70)	17 (44)
Mean CCT ± SD, µm	530.05 ± 34	536.33 ± 28	526.42 ± 37
Ethnicity, n (%)			
African American	7 (11)	3 (11)	4 (10)
Asian	34 (52)	17 (63)	17 (44)
Caucasian	11 (16)	1 (4)	10 (26)
Hispanic	10 (15)	4 (15)	6 (15)
Other	4 (6)	2 (7)	2 (5)

CCT, central corneal thickness; C/D, cup-to-disk.

\*Based on angle-opening distance 500 (AOD500) classification. Narrower is defined as AOD500 <200 µm and wide as >200 µm.

Intraocular pressure in the entire group dropped from 16.1±3.9 mm Hg to 13.2±3.1 mm Hg at 1 year after surgery (*P*<.001). In the narrower-angle group, as classified by gonioscopy criteria, the IOP was reduced from 16.6±4 mm Hg to 12.3±3 mm Hg at 1 year (4.2±3 mm Hg, 26%, *P*<.001); the wide-angle group had a decrease from 15.8±4 to 13.6±3 at 1 year (2.2±3 mm Hg, 14%, *P*<.001) (*P*=.027 for the difference between the narrower-angle vs wide-angle groups). Using the median AOD500 cutoff of 200 µm, the narrower-angle group had a reduction from 16.5±5 to 13.1±3 mm Hg (3.4±3 mm Hg, 21%, *P*<.001) at 1 year and the wide-angle group had a decrease from 15.8±4 to 13.2±3 mm Hg (2.5±3 mm Hg, 16%, *P*<.001) at 1 year (*P*=.031 for the difference between the groups) (Table 3).

Table 4 shows the anterior segment parameters from AS-OCT that were evaluated as potential predictors among the whole group. We used a multivariate mixed-effects model that adjusted for nonnormality (robust linear effects regression) and included age, gender, central corneal thickness, and preoperative IOP as potential confounders. The use of mixed-effects regression adjusted for the use of both eyes in some of the subjects. The outcome variable was IOP reduction at 1 year ( $IOP_{preop} - IOP_{postop}$ ), such that a reduction in IOP (eg, from preoperative 16 mm Hg to postoperative 14 mm Hg) is a positive value (+2 mm Hg).

Parameters that were significantly associated with IOP reduction were preoperative IOP, lens vault, iris thickness at 750 and 2000 µm from the scleral spur, and iris area (Table 4). Lens vault represents how much the anterior lens extends forward beyond the horizontal line joining the scleral spurs. It is an indirect measure of the anterior extent of the lens-iris diaphragm and the narrowness of the anterior chamber angle. Iris thickness at 750 µm (IT750) and at 2000 µm (IT2000) from the scleral spur represents the anterior-posterior iris thickness nearer the angle vs the pupil, respectively. In a general sense, iris area denotes the two-dimensional representation of iris thickness. IT750, IT2000, and iris area often are colinearly related, although they also represent different anatomical aspects of the iris, and their relationships may vary in different individuals and groups. In this particular study, IT750 may be more relevant as an indicator of the angle status and risk for narrow angles. However, iris area is also relevant and its dynamic change has been related to angle closure.

**TABLE 3. INTRAOCULAR PRESSURE REDUCTION AT 1 YEAR FOLLOW-UP IN NARROWER-ANGLE (N=20 EYES BY GONIOSCOPY, N=27 EYES BY AOD500) AND WIDE-ANGLE (N= 46 EYES FOR GONIOSCOPY, 39 EYES BY AOD500) GLAUCOMA GROUPS**

CRITERIA	MEAN IOP DROP (mm HG)		P VALUE*	ADJUSTED P VALUE†
	WIDE ANGLE‡	NARROWER ANGLE‡		
Gonioscopy	4.2 ± 3	2.2 ± 3	.013	.027
AOD500	3.4 ± 3	2.5 ± 3	.016	.031

AOD500, angle-opening distance at 500 µm from the scleral spur; IOP, intraocular pressure.  
\*Univariate *P* value.  
†Mixed-effects regression adjusting for age, gender, central corneal thickness, and basal IOP.  
‡AOD500 definition of narrower is <200 µm and of wide is >200 µm.

**TABLE 4. ASSOCIATION OF ANTERIOR SEGMENT ANATOMICAL PARAMETERS FROM ANTERIOR SEGMENT OPTICAL COHERENCE TOMOGRAPHY (AS-OCT) WITH INTRAOCULAR PRESSURE LOWERING IN GLAUCOMA AT 1-YEAR FOLLOW-UP IN PATIENTS WITH GLAUCOMA\***

PARAMETER†	β LEVEL (95% CI)	P VALUE‡
IT750 (mm)	.70 (.2, 1.2)	<b>.0063</b>
IT2000 (mm)	.61 (.054, 1.2)	<b>.032</b>
IA (mm <sup>2</sup> )	.12 (.011, .23)	<b>.031</b>
ICurv (mm)	-.16 (-.97, .64)	.69
ACD (mm)	.43 (-.016, .88)	.06
ACW (mm)	-.3 (-1.7, 1.1)	.67
LV (mm)	.93 (.25, 1.6)	<b>.0073</b>
ACA (mm <sup>2</sup> )	.033 (-.083, .15)	.58

ACA, anterior chamber area; ACD, anterior chamber depth; ACW, anterior chamber width; IA, iris area; ICurv, iris curvature; IT750, IT2000, iris thickness at 750 µm and 2000 µm from the scleral spur, respectively; LV, lens vault.

\*Mixed-effects regression adjusting for age, gender (reference group female), ethnicity (reference group African American), and central corneal thickness.

†Parameters are defined in detail in the text.

‡Significant values are in bold.

These significant parameters and their specific correlations with IOP reductions were lens vault ( $\beta$  .930,  $P=.0073$ ), IT750 ( $\beta$  .70,  $P=.0063$ ), IT2000 ( $\beta$  .61,  $P=.032$ ), and iris area ( $\beta$  .12,  $P=.031$ ). The  $\beta$  value represents the proportional change in the predictor per mm Hg of IOP reduction, according to the statistical model. For example, with lens vault, for each increase of 0.93 mm (or 930 µm), there would be a 1 mm Hg greater reduction in IOP. For IT750, the association is such that every 0.70 mm (700 µm) increase is associated with a 1 mm Hg greater IOP reduction.

The parameters anterior chamber depth and anterior chamber width represent the one-dimensional quantifications of the anterior chamber, and anterior chamber area is the two-dimensional representative. These values were not significantly associated with IOP drop in our modeling.

In all statistical models incorporating the different anatomical parameters, preoperative IOP was significantly correlated with IOP drop ( $P<.001$ ). Age and gender were not statistically significantly associated with IOP change after surgery in any of the regressions.

In the reproducibility study, we randomly selected 10 AS-OCT images and the grader re-identified the scleral spurs. AOD500 was the outcome variable assessed, and it showed an ICC of 0.86, which is considered excellent and consistent with prior data.<sup>31</sup>

## DISCUSSION

In this prospective study of the predictive power of anatomical and clinical parameters for IOP reduction after Phaco in glaucomatous eyes, we found that the mean IOP reduction was 4.2±3 mm Hg in narrower-angle eyes and 2.2±3 mm Hg in wide-angle glaucomatous eyes ( $P=.027$  for the difference), using gonioscopy criteria for classification. When we divided the groups into narrower-angle vs wide-angle cohorts based on the angle parameter AOD500, we also found that the narrower-angle group had significantly greater IOP

change ( $3.4 \pm 3$  mm Hg vs  $2.5 \pm 3$  mm Hg, respectively,  $P=.031$ ). Furthermore, we found that lens vault, iris thickness, and iris area—all measures that are associated with angle closure—are significant predictors of IOP reduction after Phaco.

Most published studies have demonstrated that Phaco lowers IOP in both nonglaucomatous and glaucomatous eyes (Table 1).<sup>1-34</sup> A recent evidence-based review from the American Academy of Ophthalmology describes the IOP lowering in different forms of glaucoma.<sup>30</sup> The reduction was lowest in the POAG group, although it is still significant with 13% lowering in IOP together with 13% lowering in number of glaucoma medications used. Eyes with exfoliation syndrome had greater IOP (20%) and medication (35%) reduction. The efficacy in closed-angle glaucoma is even more pronounced, with 29% IOP reduction and 53% medication reduction in chronic angle-closure glaucoma and 71% IOP reduction and almost no need for postsurgery medications in acute angle-closure glaucoma. It is notable that filtering surgery was very uncommon after cataract surgery; among the studies reviewed, the need for filtering surgery was between 0.6% and 0.8% among controlled POAG patients at 1 year.

Why is there such a discrepancy in IOP response between the open-angle glaucoma vs the closed-angle glaucoma groups? Is it simply the anatomical differences between the groups that explain the substantial difference in efficacy of Phaco? Could there be a proportional response in nonclosed angles, depending on the narrowness of an angle?

Our group has previously demonstrated in nonglaucomatous eyes that undergoing Phaco was associated with statistically significant IOP reduction and that the decrease was greater in eyes with narrower vs wide angles.<sup>32</sup> We set a cutoff for narrower angles as having three or more quadrants with grade 2 or less by the Shaffer grading system on gonioscopy. In the present study, we utilized the same cutoff values and found that in glaucomatous eyes that were receiving topical glaucoma therapy (medications were kept the same after surgery), the IOP reduction was statistically greater in eyes classified as narrower compared to wide ( $4.2 \pm 3$  mm Hg vs  $2.2 \pm 3$  mm Hg, respectively,  $P=.027$ ). Using the AOD500 median from our pilot study as a cutoff to separate narrower vs wide angles, we found a similar difference in IOP reduction ( $3.4 \pm 3$  mm Hg vs  $2.5 \pm 3$  mm Hg, respectively,  $P=.031$ ). These results are not only statistically significant, but may be clinically relevant in eyes that need further IOP lowering and/or patients who strongly prefer reducing their medication load.

It may be argued that the IOP reduction is not clinically significant in eyes with open or wide angles. It has been suggested that based on the safety profile of minimally invasive glaucoma surgeries (MIGS), this emerging category of surgeries could be combined with all cataract surgeries in mild to moderate glaucoma cases with virtually no measurable increase in adverse effects compared to Phaco alone.<sup>56</sup> However, in a prospective study that compared Phaco to Phaco plus iStent in a group of subjects with mild to moderate open-angle glaucoma, Phaco alone was highly effective in achieving the success target of  $\geq 20\%$  IOP reduction (48% of cases).<sup>57</sup> The addition of the iStent procedure increases the success rate (66% of cases), although the added efficacy may be relatively small compared to the overall effect of the Phaco itself. Trabectome is another MIGS that is approved for use. However, the efficacy of this procedure is variable and usually does not achieve IOPs below the midteens.<sup>58,59</sup> Both procedures are approved by the US Food and Drug Administration and are currently commercially available. The CyPass (Alcon Laboratories, Inc) suprachoroidal shunt has recently been approved and is now available.<sup>60-63</sup> The clinical outcomes at 2 years follow-up in a prospective study comparing Phaco vs Phaco with CyPass show that there is significant improvement in the success rate with the concurrent CyPass surgery.<sup>60</sup> However, similar to the study with the iStent, eyes receiving Phaco alone achieved success ( $\geq 20\%$  IOP reduction) in a large proportion of cases (60%). Thus, although there may be added efficacy with MIGS, the effect can be considered relatively minor in light of the strong effect of the Phaco surgery alone. In fact, it can be interpreted that these studies provide excellent prospective data to support Phaco as an excellent surgery for lowering IOP by itself. Since the costs to the healthcare system of adding a MIGS procedure are substantial, the clinician will need to assess on a case-by-case basis the relative cost-effectiveness of performing Phaco alone vs Phaco combined with MIGS in eyes with glaucoma.

Issues related to MIGS, besides efficacy, include risk for complications, surgeon training and learning curve, availability, and costs to the patient and society. As with any procedure, there are possible adverse events that can happen with any MIGS. The iStent likely has the least chance for injury, although misplacement of the device can lead to malfunction or need for removal if it becomes displaced into the anterior chamber.<sup>57,64,65</sup> Trabectome often leads to hyphema and associated poor quality of vision.<sup>58,66</sup> In developing countries—where the majority of glaucoma resides—availability of MIGS will be limited or nonexistent due to regulatory approval, cost, and/or proper training of the surgeons. In such areas, cataract surgery is usually available and may present the best management option, since medical and laser therapy for glaucoma is often limited or unavailable. The relevance of our results is that they may help guide surgeons as to when Phaco may be appropriate for helping to reduce IOP and the medication load among glaucoma subjects who are at risk for progression. As an example, if a patient with mild-moderate glaucoma has narrower angles and high lens vault, Phaco alone may be the optimal choice, as IOP reduction will be greater and a concomitant MIGS may be more challenging, especially if performed prior to Phaco, when view of the angle is more limited in narrower-angle eyes.

There are controversy and mixed data related to the mechanisms by which Phaco lowers IOP. A study by Wang and colleagues<sup>67</sup> showed that Phaco in the *in vitro* setting elicits cytokines, which may account for the IOP reduction. Cultured trabecular meshwork cells from both normal and glaucomatous eyes were treated with 60 seconds of Phaco ultrasound at a power of 70%. Interleukin 1 $\alpha$  (IL-1 $\alpha$ ) was induced in normal trabecular meshwork cells, and increased levels were detected in glaucomatous trabecular meshwork cells. Similarly, endothelial leukocyte adhesion molecule-1 was induced in normal cells; however, glaucomatous cells had constitutive expression at baseline and did not have an increase in amount after Phaco. Also, NF- $\kappa$ B (a stress-modifying transcription factor) was expressed in the cytoplasm of normal cells and nucleus of trabecular meshwork cells at baseline, but after Phaco, NF- $\kappa$ B was present in the nucleus of the normal cells. It is speculated by the investigators that these cytokines and intracellular mediators may be part of a stress response that is related to the IOP reduction after Phaco.

A theory that is espoused by our group and others is that the IOP-lowering effect is primarily due to the anatomical changes in the



anterior segment, including the anterior chamber angle.<sup>7,31,32,46,68,69</sup> A recent study by Sengupta and colleagues<sup>70</sup> found that the IOP reduction is significant and similar in patients receiving Phaco as compared to manual small-incision cataract surgery (MSICS). In fact, they reported that there was greater reduction in IOP in the MSICS group (compared with the Phaco group) at 1 month ( $\Delta\text{IOP} = 2.6 \pm 2.9$  vs  $1.6 \pm 2.9$  mm Hg;  $P = .002$ ) and 3 months ( $\Delta\text{IOP} = 3.4 \pm 2.8$  vs  $2.8 \pm 2.7$  mm Hg;  $P = .05$ ). However, at 6 months, mean IOP reduction was comparable between the groups ( $\Delta\text{IOP} = 2.7 \pm 2.9$  mm Hg for MSICS vs  $2.6 \pm 2.6$  mm Hg for Phaco;  $P = .70$ ).<sup>70</sup> The similarity in IOP reduction without ultrasound assistance used for Phaco suggests that the IOP reduction is not related to ultrasound activation of cytokines. Although this group did not find that baseline parameters from the AS-OCT predicted IOP reduction (however, eyes with IOP reduction did have a greater degree of widening of AOD500 than eyes with IOP increase), the study was conducted in nonglaucoma subjects with normal IOPs. It may be that in patients with glaucoma, the correlation with anterior segment factors is more pronounced and significant. In the present study, the average IOP reduction was slightly greater ( $2.9 \pm 3$  mm Hg in our study vs  $2.6 \pm 2.6$  mm Hg in that by Sengupta and colleagues), and with the wider range in reductions, there may be a greater chance to find an association. Furthermore, our analysis was different in that we established from the outset a cutoff for a commonly used anterior chamber angle parameter (AOD500) to distinguish narrower vs wide angles.

Some studies have found a correlation of anterior chamber depth with IOP reduction,<sup>33,34</sup> but others have not.<sup>8,31,36,37</sup> In our present study, we did not find a significant correlation of anterior chamber depth (or its two-dimensional correlate, anterior chamber area) with IOP reduction. However, lens vault was a predictor, a finding that is also supported by our prior study in nonglaucomatous eyes.<sup>31</sup> Lens vault represents the elevation of the anterior lens above the line between the two scleral spurs. A greater lens vault means that the lens-iris diaphragm is more anterior, which is associated with a narrower anterior chamber angle and higher risk for angle closure.<sup>71,72</sup> In fact, lens vault has been noted to have the greatest quantitative correlation with AOD in a study of Chinese Singaporeans.<sup>72</sup>

Similarly, iris thickness (IT750) and iris area are significantly correlated with narrower anterior chamber angles.<sup>71,72</sup> The finding that IT750, IT2000, and iris area are predictive of IOP drop in our study may lend support that crowding of the angle can be associated with the IOP outcome after Phaco. Pradhan and colleagues<sup>8</sup> had also found that iris cross-sectional area was associated with postoperative IOP in their study of predictors of IOP reduction. Since the dynamic change in the iris with physiologic or pharmacologic dilation has been linked to angle closure,<sup>73,74</sup> future studies evaluating the light-dark or mydriatic change of the iris and ciliary body before and after cataract surgery may be helpful in further understanding the mechanisms by which IOP is lowered.

Another area where there is support for angle and anterior chamber status in lowering IOP is the relative poor reduction seen in eyes with myopia, especially high myopia.<sup>32,75-77</sup> In fact, in some studies, there is an overall IOP increase among higher myopes.<sup>75,77</sup> Eyes with high myopia are associated with having wide anterior chamber angles,<sup>78,79</sup> suggesting that this extreme is associated with lower (or no) IOP reduction with Phaco.

How does a narrow angle before surgery possibly lead to greater IOP lowering? It may be that Phaco alters the position and anatomy of the ciliary body and thus the scleral spur, and eyes that have narrower angles will have greater change, thus leading to greater IOP change.

Cataract extraction appears to have a substantial effect on the dynamics of the ciliary body, as shown in a study by Park and colleagues.<sup>80</sup> Pilocarpine was used as a stimulus for muscle contraction (simulating accommodation), and it was found that Phaco induced significant centripetal movement of the ciliary body (induced by pilocarpine) compared to preoperative mobility. Posterior displacement of the iris may alter the ciliary body shape, and also the posterior lens capsule shift produced by lens extraction may lead to posterior movement of the ciliary process. The location and mobility of the ciliary body are related to aqueous humor outflow and trabecular meshwork morphology in animal models<sup>81</sup>; hence, it may be postulated that Phaco can have a direct effect on ciliary body anatomy and physiology and thus on the outflow system of the eye, and this effect can be particularly enhanced in eyes with a crowded anterior chamber angle prior to surgery.

Kee and colleagues<sup>82</sup> used in vivo tonography in subjects having Phaco and found an increase in outflow facility after cataract extraction. Intraocular pressure was reduced by a mean of 2.4 mm Hg in the group as well. It was speculated by the investigators that there is a constant tension on the ciliary body and the zonules induced by the phakic lens; if the lens is removed, the zonular tension is decreased, and theoretically this factor may also affect the ciliary body mobility and aqueous outflow. In eyes that have greater lens vault, the preoperative tension on the ciliary body may draw it more forward, but this is relieved with Phaco, allowing relaxation of the ciliary body. Consequently, there would be less forward tension on the scleral spur and thus widening of the trabecular meshwork and increase in outflow facility—again, potentially greater among eyes that had narrower angles and greater lens vault prior to surgery.

In a recent study by Zhao and colleagues,<sup>83</sup> it was shown that Phaco results in an expansion of Schlemm's canal and widening of the trabecular meshwork. The investigators used high-resolution swept-source OCT and found that the widening of the Schlemm's canal area and diameter was correlated with the IOP reduction observed after Phaco at 6 months. The investigators suggest that the depression of the lens posteriorly after cataract surgery likely causes posterior displacement of the scleral spur, thus expanding the trabecular meshwork and the lumen of Schlemm's canal. They note that prior studies have shown that angle parameters have been correlated with IOP reduction, although they did not find this in their study, and therefore it is unclear if the anterior chamber angle parameters are linked to IOP reduction through the expansion of Schlemm's canal.

Our study has several limitations, including the small sample size and relatively short follow-up of 1 year. We included both eyes of 26 of the participants, but this limitation in the sample size is compensated by the fact that mixed-effects regression corrects for two different measures given by the same subject in the model. Also, measurements of anterior segment parameters are partly dependent on manual identification of the scleral spurs, which may introduce human error and bias. We endeavored to minimize these factors by

having a single grader of the AS-OCT images masked to the clinical results, and then testing the reproducibility of the measurements from the same observer. Our ICC of 0.86 supports that we had excellent reproducibility of the measurements and is consistent with prior results.<sup>31</sup> Anterior chamber angle parameters (AOD500) and iris values (IT750, IT2000, iris area, iris curvature) represent focal anterior segment parameters and were not averaged over the temporal and nasal sectors in this report as has been done in some prior studies using AS-OCT. Instead, we utilized only the nasal segments of the AS-OCT images in our analyses, since the surgery site is temporal, which may affect postoperative measurements. We anticipate future comparisons of preoperative vs postoperative scans and thus have retained the focus on the nasal sections, as we have in prior studies. Anterior segment biometry parameters (lens vault, anterior chamber depth, anterior chamber area, anterior chamber volume) were reflective of the entire anterior segment and not just the nasal or temporal sides. Another limitation of our study is the relatively high proportion of Asian subjects (approximately half of the entire group and two-thirds of the narrower-angle group). This disproportionate representation reflects the population distribution of San Francisco and the high preponderance of narrow(er) angles among Asians. This racial difference in population distribution in our study may limit the generalizability of our findings to other ethnic groups. As a result, there may be differences in various populations that deserve further study.

It should be noted that often the IOP-lowering effect of Phaco attenuates over time, whereas glaucoma is usually a lifelong disease. Thus, it is possible that the modest differences in IOP reduction in POAG eyes with differing degrees of “openness” at 1 year may have a relatively small impact on the course of the disease over a lifetime. With the further development and approval by regulatory agencies of safe and effective glaucoma procedures, their concomitant use at the time of Phaco may be warranted.

In summary, this is the first study to show that POAG eyes with narrower angles, whether determined by gonioscopy grading or by quantitative angle imaging, have greater IOP lowering than eyes with wide-open angles. Furthermore, we found that lens vault, iris thickness, and iris area were all significantly correlated with IOP reduction. One of the strengths of this study is that the glaucoma medication regimen was kept constant before and after the Phaco surgery, thus isolating the IOP effect. Our findings may benefit doctors and patients in determining whether to select cataract surgery alone as a treatment for a given glaucoma situation. Future larger clinical trials can help to validate our findings and may employ washout of glaucoma medications to help assess actual IOP reduction under untreated conditions.

## ACKNOWLEDGMENTS

*Funding/Support:* This study was supported by the American Glaucoma Society Mid-Career Grant (Dr Lin); National Eye Institute P30 Core Grant (EY002162) for Vision Research (University of California, San Francisco); Research to Prevent Blindness Unrestricted Grant (University of California, San Francisco); and That Man May See, Inc. (Dr Lin)

*Financial Disclosures:* Dr Lin has been an advisor/consultant for Allergan, Plc; Iridex Corporation; Aleyegn, Inc.; and Alimera Sciences, Inc. He has also received travel support and honoraria from the Glaucoma Fellows Program conducted by *Review of Ophthalmology* and supported by an unrestricted grant from Alcon Laboratories, Inc. Dr Pasquale has been a paid consultant for Bausch & Lomb and an unpaid consultant for Novartis. He has received travel support from The Glaucoma Foundation and travel support and an honorarium from the Glaucoma Fellows Program conducted by *Review of Ophthalmology* and supported by an unrestricted grant from Alcon Laboratories, Inc. Dr Masis and Dr Porco have no financial disclosures.

*Author Contributions:* Design of the study (S.C.L., M.M., T.C.P.); Conduct of the study (S.C.L., M.M.); Collection of data (S.C.L., M.M.); Management of data (S.C.L., M.M.); Analysis of data (S.C.L., M.M., T.C.P., L.R.P.); Interpretation of the data (S.C.L., M.M., T.C.P., L.R.P.); Preparation of manuscript (S.C.L., M.M.); Review of manuscript (S.C.L., M.M., T.C.P., L.R.P.); and Approval of manuscript (S.C.L., M.M., T.C.P., L.R.P.).

## REFERENCES

1. Poley BJ, Lindstrom RL, Samuelson TW. Long-term effects of phacoemulsification with intraocular lens implantation in normotensive and ocular hypertensive eyes. *J Cataract Refract Surg* 2008;34:735-742.
2. Poley BJ, Lindstrom RL, Samuelson TW, Schulze R Jr. Intraocular pressure reduction after phacoemulsification with intraocular lens implantation in glaucomatous and nonglaucomatous eyes; evaluation of a causal relationship between the natural lens and open-angle glaucoma. *J Cataract Refract Surg* 2009;35:1946-1955.
3. Mathalone N, Hyams M, Neiman S, Buckman G, Hod Y, Geyer O. Long-term intraocular pressure control after clear corneal phacoemulsification in glaucoma patients. *J Cataract Refract Surg* 2005;31:479-483.
4. Shingleton BJ, Pasternack JJ, Hung JW, O'Donoghue MW. Three and five year changes in intraocular pressures after clear corneal phacoemulsification in open angle glaucoma patients, glaucoma suspects, and normal patients. *J Glaucoma* 2006;15:494-498.
5. Wang F, Wu ZH. Phacoemulsification versus combined phacotrabeculectomy in the treatment of primary angle closure glaucoma with cataract: a meta-analysis. *Int J Ophthalmol* 2016;9(4):597-603.
6. Slabaugh MA, Bojikian KD, Moore DB, Chen PP. The effect of phacoemulsification on intraocular pressure in medically controlled open-angle glaucoma patients. *Am J Ophthalmol* 2014;157(1):26-31.
7. Shin HC, Subrayan V, Tajunisah I. Changes in anterior chamber depth and intraocular pressure after phacoemulsification in eye with occludable angles. *J Cataract Refract Surg* 2010;36:1289-1295.
8. Pradhan S, Leffler CT, Wilkes M, Mahmood MA. Preoperative iris configuration and intraocular pressure after cataract surgery. *J Cataract Refract Surg* 2012;38:117-123.

9. Guan H, Mick A, Porco T, et al. Preoperative factors associated with IOP reduction after cataract surgery. *Optom Vis Sci* 2013;90:179-184.
10. Suzuki R, Kuroki S, Fujiwara N. Ten-year follow-up of intraocular pressure after phacoemulsification and aspiration with intraocular lens implantation performed by the same surgeon. *Ophthalmologica* 1997;211:79-83.
11. Shoji T, Tanito M, Takahashi H et al. Phacoviscocanalostomy versus cataract surgery only in patients with coexisting normal-tension glaucoma: midterm outcomes. *J Cataract Refract Surg*. 2007;33(7):1209-16.
12. Mansberger SL, Gordon MO, Jampel H et al. Reduction in intraocular pressure after cataract extraction: the Ocular Hypertension Treatment Study. *Ophthalmology*. 2012;119:1826-1831.
13. Husain R, Gazzard G, Aung T et al. Initial management of acute primary angle closure: a randomized trial comparing phacoemulsification with laser peripheral iridotomy. *Ophthalmology*. 2012;119:2274-2281.
14. Shrivastava A, Singh K. The impact of cataract surgery on glaucoma care. *Curr Opin Ophthalmol* 2014;25:19-25.
15. Lam DS, Leung DY, Tham CC, et al. Randomized trial of early phacoemulsification versus peripheral iridotomy to prevent intraocular pressure rise after acute primary angle closure. *Ophthalmology* 2008;115:1134-1140.
16. Lee RY, Chen RI, Kasuga T, et al. The effect of cumulative dissipated energy on changes in intraocular pressure after uncomplicated cataract surgery by phacoemulsification. *J Glaucoma* 2015; 25(7):565-570.
17. Damji KF, Konstas AG, Liebmann JM, et al. Intraocular pressure following phacoemulsification in patients with and without exfoliation syndrome: a 2 year prospective study. *Br J Ophthalmol* 2006;90:1014-1018.
18. Casson RJ, Riddell CE, Rahman R, et al. Long-term effect of cataract surgery on intraocular pressure after trabeculectomy: extracapsular extraction versus phacoemulsification. *J Cataract Refract Surg* 2002;28:2159-2164.
19. Shrivastava A, Singh K. The effect of cataract extraction on intraocular pressure. *Curr Opin Ophthalmol* 2010;21:118-122.
20. Shingleton BJ, Gamell LS, O'Donoghue MW, Bayliss SL, King R. Long-term changes in intraocular pressure after clear corneal phacoemulsification: normal patients versus glaucoma suspect and glaucoma patients. *J Cataract Refract Surg* 1999;25:885-890.
21. Azuara-Blanco A, Burr J, Ramsay C, et al. Effectiveness of early lens extraction for the treatment of primary angle closure glaucoma (EAGLE): a randomized controlled trial. *Lancet* 2016;388:1389-1397.
22. Iancu R, Corbu C. Intraocular pressure after phacoemulsification in patients with uncontrolled primary open angle glaucoma. *J Med Life* 2014;15;7(1):11-16.
23. Mierzejewski A, Eliks I, Kałuzny B, et al. Cataract phacoemulsification and intraocular pressure in glaucoma patients. *Klin Oczna* 2008;110(1-3):11-17.
24. Hayashi K, Hayashi H, Nakao F. Effect of cataract surgery on intraocular pressure control in glaucoma patients. *J Cataract Refract Surg* 2001;27(11):1779-1786.
25. Shams P, Foster P. Clinical outcomes after lens extraction for visually significant cataract in eyes with primary angle closure. *J Glaucoma* 2012;21(8):545-550.
26. Moghimi S, Latifi G, ZandVakil N, et al. Phacoemulsification versus combined phacoemulsification and viscosgonioplasty in primary angle-closure glaucoma: a randomized clinical trial. *J Glaucoma* 2015;24(8):575-582.
27. Tham CC, Kwong YY, Baig N, et al. Phacoemulsification versus combined phacotrabeulectomy in medically uncontrolled chronic angle closure glaucoma without cataracts. *Ophthalmology* 2013;120(1):62-67.
28. Tham CC, Kwong YY, Leung DY, et al. Phacoemulsification versus combined phacotrabeulectomy in medically uncontrolled chronic angle closure glaucoma with cataract. *Ophthalmology* 2009;116(4):725-731.
29. Tham CC, Kwong YY, Leung DY, et al. Phacoemulsification versus trabeculectomy in medically controlled chronic angle closure glaucoma with cataract. *Ophthalmology* 2008;115(12):2167-2173.
30. Chen PP, Lin SC, Junk AK. The effect of phacoemulsification on intraocular pressure in glaucoma patients: a report by the American Academy of Ophthalmology. *Ophthalmology* 2015;122(7):1294-1307.
31. Huang G, Gonzalez E, Lee R, Chen YC, He M, Lin SC. Association of biometric factors with anterior chamber angle widening and intraocular pressure reduction after uneventful phacoemulsification for cataract. *J Cataract Refract Surg* 2012;38:108-116.
32. Huang G, Gonzalez E, Peng PH, et al. Anterior chamber depth, iridocorneal angle width, and intraocular pressure changes after phacoemulsification: narrow vs open iridocorneal angles. *Arch Ophthalmol* 2011;129:1283-1290.
33. Issa SA, Pacheco J, Mahmood U, Nolan J, Beatty S. A novel index for predicting intraocular pressure reduction following cataract surgery. *Br J Ophthalmol* 2005;89:543-546.
34. Kashiwagi K, Kashiwagi F, Tsukahara S. Effects of small-incision phacoemulsification and intraocular lens implantation on anterior chamber depth and intraocular pressure. *J Glaucoma* 2006;15(2):103-109.
35. Moghimi S, Chen R, Hamzeh N, et al. Qualitative evaluation of anterior segment in angle closure using anterior segment optical coherence tomography. *J Curr Ophthalmol* 2016;28(4):170-175.
36. Moghimi S, Johari M, Mahmoudi A, et al. Predictors of intraocular pressure change after phacoemulsification in patients with pseudoexfoliation syndrome. *Br J Ophthalmol* 2017;101:283-289.
37. Moghimi S, Abdi F, Lafiti G, et al. Lens parameters as predictors of intraocular pressure changes after phacoemulsification. *Eye* 2015;29:1469-1476.
38. Radhakrishnan S, Rollins A, Roth J, et al. Real-time optical coherence tomography of the anterior segment at 1310 nm. *Arch Ophthalmol* 2001;119:1179-1185.
39. Nolan W, See J, Chew P, et al. Detection of primary angle closure using anterior segment optical coherence tomography in Asian eyes. *Ophthalmology* 2007;114:873-875.

40. Radhakrishnan S, Goldsmith J, Huang D, et al. Comparison of optical coherence tomography and ultrasound biomicroscopy for detection of narrow anterior chamber angles. *Arch Ophthalmol* 2005;123:1053-1059.
41. Konstantopoulos A, Hossain P, Anderson D. Recent advances in ophthalmic anterior segment imaging: a new era for ophthalmic diagnosis? *Br J Ophthalmol* 2007;91:551-557.
42. Reinstein D, Gobbe M, Archer T. Anterior segment biometry: a study and review of resolution and repeatability data. *J Refract Surg* 2012;28(7):509-520.
43. Sakata L, Lavanya R, Friedman D, et al. Comparison of gonioscopy and anterior segment optical coherence tomography in detecting angle closure in different quadrants of the anterior chamber angle. *Ophthalmology* 2008;115:769-774.
44. Sakata L, Lavanya R, Friedman D, et al. Assessment of the scleral spur in anterior segment optical coherence tomography images. *Arch Ophthalmol* 2008;126:181-185.
45. Hu CX, Mantravadi A, Zangalli C, et al. Comparing gonioscopy with Visante and Cirrus optical coherence tomography for anterior chamber angle assessment in glaucoma patients. *J Glaucoma* 2016;25(2):177-183.
46. Coh P, Chen R, Hsu C, et al. Lens position parameters as predictors of intraocular pressure reduction after cataract surgery in glaucomatous versus nonglaucomatous eyes. *Invest Ophthalmol Vis Sci* 2016;57(6):2593-2599.
47. Sakata L, Wong T, Wong H, et al. Comparison of Visante and slit-lamp anterior segment optical coherence tomography in imaging the anterior chamber angle. *Eye* 2010;24:578-587.
48. Wu R, Nongpiur M, He M, et al. Association of narrow angles with anterior chamber area and volume measured with anterior-segment optical coherence tomography. *Arch Ophthalmol* 2011;129(5):569-574.
49. Nongpiur M, Gong T, Lee H, et al. Subgrouping of primary angle-closure suspects based on anterior segment optical coherence tomography parameters. *Ophthalmology* 2013;120(12):2525-2531.
50. Nongpiur M, Atalay E, Gong T, et al. Anterior segment imaging-based subdivision of subjects with primary angle-closure glaucoma. *Eye* 2016;doi:10.1038. eye.2016.267. [Epub ahead of print]
51. Yang HS, Lee J, Choi S. Ocular biometric parameters associated with intraocular pressure reduction after cataract surgery in normal eyes. *Am J Ophthalmol* 2013;156(1):89-94.
52. Foster P, Buhrmann R, Quigley H, et al. The definition and classification of glaucoma in prevalence surveys. *Br J Ophthalmol* 2002;86:238-242.
53. Lowe RF. Aetiology of the anatomical basis for primary angle closure glaucoma. Biometrical comparisons between normal eyes and eyes with primary open angle glaucoma. *Br J Ophthalmol* 1970;54:161-169.
54. Shabana N, Aquino M. Quantitative evaluation of anterior chamber parameters using anterior segment optical coherence tomography in primary angle closure mechanisms. *Clin Exp Ophthalmol* 2012;40:792-801.
55. Nongpiur ME, He M, Amerasinghe H, et al. Lens vault, thickness and position in Chinese subjects with angle closure. *Ophthalmology* 2011;118:474-479.
56. Samuelson T. Microinvasive glaucoma surgery-coming of age. Guest editorial. *J Cataract Refract Surg* 2014;40(8):1253-1254.
57. Samuelson TW, Katz LJ, Wells JM, et al. Randomized evaluation of the trabecular micro-bypass stent with phacoemulsification in patients with glaucoma and cataract. *Ophthalmology* 2011;118:459-467.
58. Kaplowitz K, Bussell I, Honkanen R, et al. Review and meta-analysis of ab-interno trabeculectomy outcomes. *Br J Ophthalmol* 2016;100:594-600.
59. Hu K, Gazzard G, Bunce C, Wormald R. Ab interno trabecular bypass surgery with trabectome for open angle glaucoma. *Cochrane Database Syst Rev* 2016;Aug 15(8):CD011693.
60. Vold S, Ahmed II, Craven R, et al. Two-year COMPASS trial results: supraciliary microstenting with phacoemulsification in patients with open-angle glaucoma and cataracts. *Ophthalmology* 2016;123:2103-2112.
61. Hoeh H, Ahmed II, Grisanti S, et al. Early postoperative safety and surgical outcomes after implantation of a suprachoroidal micro-stent for the treatment of open-angle glaucoma concomitant with cataract surgery. *J Cataract Refract Surg* 2013;39:431-437.
62. Hoeh H, Vold SD, Ahmed IK, et al. Initial clinical experience with the CyPass Micro-Stent: safety and surgical outcomes of a novel supraciliary microstent. *J Glaucoma* 2016;25:106-112.
63. García-Feijoo J, Rau M, Grisanti S, et al. Supraciliary microstent implantation for open-angle glaucoma failing topical therapy: 1-year results of a multicenter study. *Am J Ophthalmol* 2015;159:1075-1081.
64. Fea A. Phacoemulsification versus phacoemulsification with micro-bypass stent implantation in primary open-angle glaucoma: randomized double-masked clinical trial. *J Cataract Refract Surg* 2010;36:407-412.
65. Craven ER, Katz LJ, Wells JM, Giamborcaro JE; iStent Study Group. Cataract surgery with trabecular micro-bypass stent implantation in patients with mild-to-moderate open-angle glaucoma and cataract: two-year follow-up. *J Cataract Refract Surg* 2012;38(8):1339-1345.
66. Akil H, Chopra V, Huang A, et al. Clinical results of ab interno trabeculotomy using the Trabectome in patients with pigmentary glaucoma compared to primary open angle glaucoma. *Clin Exp Ophthalmol* 2016;44(7):563-569.
67. Wang N, Chintala SK, Fini ME, Schuman JS. Ultrasound activates the TM ELAM-1/IL-1/NF-kappaB response: a potential mechanism for intraocular pressure reduction after phacoemulsification. *Invest Ophthalmol Vis Sci* 2003;44:1977-1981.
68. Lee R, Kasuga T, Cui Q, et al. Ethnic differences in intraocular pressure reduction and changes in anterior segment biometric parameters following cataract surgery by phacoemulsification. *Clin Exp Ophthalmol* 2013;41(5):442-449.

69. Hsu CH, Kakigi CL, Lin SC, et al. Lens position parameters as predictors of intraocular pressure reduction after cataract surgery in nonglaucomatous patients with open angles. *Invest Ophthalmol Vis Sci* 2015;56(13):7807-7813.
70. Sengupta S, Venkatesh R, Krishnamurthy P, et al. Intraocular pressure reduction after phacoemulsification versus manual small incision cataract surgery: a randomized controlled trial. *Ophthalmology* 2016;123(8):1695-1703.
71. Lee RY, Chon BH, Lin SC, He M, Lin SC. Association of ocular conditions with narrow angles in different ethnicities. *Am J Ophthalmol* 2015;160(3):506-515.
72. Foo LL, Nongpiur ME, Allen JC, et al. Determinants of angle width in Chinese Singaporeans. *Ophthalmology* 2012;119(2):278-282.
73. Quigley HA, Silver DM, Friedman DS, et al. Iris cross-sectional area decreases with pupil dilation and its dynamic behavior is a risk factor in angle closure. *J Glaucoma* 2009;18(3):173-179.
74. Aptel F, Denis P. Optical coherence tomography quantitative analysis of iris volume changes after pharmacologic mydriasis. *Ophthalmology* 2010;117(1):3-10.
75. Cho YK. Early intraocular pressure and anterior chamber depth changes after phacoemulsification and intraocular lens implantation in nonglaucomatous eyes. Comparison of groups stratified by axial length. *J Cataract Refract Surg* 2008;34:1104-1109.
76. Rada JA, Shelton S, Norton TT. The sclera and myopia. *Exp Eye Res* 2006;82:185-200.
77. Fan F, Luo Y, Lu Y, Liu X. Reasons for early ocular hypertension after uneventful cataract surgery. *Eur J Ophthalmol* 2014;24(5):712-717.
78. Vossmerbaeumer U, Schuster AK, Fischer JE. Width of anterior chamber angle determined by OCT, and correlation to refraction and age in a German working population: the MIPH Eye & Health Study. *Graefes Arch Clin Exp Ophthalmol* 2013;251(12):2741-2746.
79. Jin P, Li M, He X, et al. Anterior-chamber angle and axial length measurements in normal Chinese children. *J Glaucoma* 2016;25(8):692-697.
80. Park KA, Yun JH, Kee C. The effect of cataract extraction on the contractility of ciliary muscle. *Am J Ophthalmol* 2008;146:8-14.
81. Kaufman P. Enhancing trabecular outflow by disrupting the actin cytoskeleton, increasing uveoscleral outflow with prostaglandins, and understanding the pathophysiology of presbyopia interrogating Mother Nature: asking why, asking how, recognizing the signs, following the trail. *Exp Eye Res* 2008;86(1):3-17.
82. Kee C, Moon SH. Effect of cataract extraction and posterior chamber lens implantation on outflow facility and its response to pilocarpine in Korean subjects. *Br J Ophthalmol* 2000;84:987-989.
83. Zhao Z, Zhu X, He W, Jiang C, Lu Y. Schlemm's canal expansion after uncomplicated phacoemulsification surgery: an optical coherence tomography study. *Invest Ophthalmol Vis Sci* 2016;57(15):6507-6512.
84. Liu CJ, Cheng CY, Ko YC, Lau LI. Determinants of long-term intraocular pressure after phacoemulsification in primary angle-closure glaucoma. *J Glaucoma* 2011;20(9):566-570.