

THE AHMED GLAUCOMA VALVE IN NEOVASCULAR GLAUCOMA (AN AOS THESIS)

BY Peter A. Netland MD PhD

ABSTRACT

Purpose: To evaluate the results of Ahmed glaucoma valve surgery in neovascular glaucoma and control patients.

Methods: In this retrospective comparative study, we reviewed 76 eyes of 76 patients, comparing the surgical outcomes in control patients (N=38) to matched neovascular glaucoma patients (N=38). Success was defined as intraocular pressure (IOP) ≥ 6 mm Hg and ≤ 21 mm Hg, without further glaucoma surgery, and without loss of light perception.

Results: Average follow-up for control and neovascular glaucoma patients was 18.4 and 17.4 months, respectively ($P = .550$). At last follow-up, mean IOP was 16.2 ± 5.2 mm Hg and 15.5 ± 12.5 mm Hg ($P = .115$) in control and neovascular glaucoma patients, respectively. Life-table analysis showed a significantly lower success for neovascular glaucoma patients compared with controls ($P = .0096$), with success at 1 year of 89.2% and 73.1%, at 2 years of 81.8% and 61.9%, and at 5 years of 81.8% and 20.6% for control and neovascular glaucoma eyes, respectively. Cox proportional hazards regression analysis showed neovascular glaucoma as a risk factor for surgical failure (odds ratio, 5.384, 95% CI, 1.22-23.84, $P = .027$). Although IOP control and complications were comparable between the two groups, visual outcomes were worse in neovascular glaucoma patients, with 9 eyes (23.7%) with neovascular glaucoma compared with no controls losing light perception vision ($P = .002$). The majority with loss of vision (5 of 9) had successful control of IOP during the postoperative period.

Conclusion: Neovascular glaucoma patients have greater risk of surgical failure after Ahmed glaucoma valve surgery compared with controls. Despite improved mean IOP with drainage implants, visual outcomes may be poor, possibly due to progression of underlying disease.

Trans Am Ophthalmol Soc 2009;107:325-342

INTRODUCTION

Outcomes of treatment of neovascular glaucoma were poor in the past,^{1,2} but understanding of the mechanisms of the disease and the prognosis for treatment have improved in recent years.^{3,4} Neovascular glaucoma has been reported to occur in over 40 ocular diseases,⁴ including, most commonly, diabetes mellitus, central retinal vein occlusion, and ocular ischemic syndrome. Most of these diseases are associated with retinal ischemia, with approximately 3% of cases of neovascular glaucoma associated with inflammation without retinal ischemia.⁵ Ischemia triggers the release of vascular endothelial growth factor (VEGF), interleukin, and other angiogenic factors that can diffuse into the anterior segment, causing neovascularization of the iris and anterior chamber angle.⁶⁻⁸ Lensectomy, Nd:YAG laser capsulotomy, or other reductions of barriers to diffusion of these angiogenic factors may be associated with a high incidence of rubeosis iridis.⁹⁻¹¹ Fibrovascular proliferation in the anterior segment may obstruct the trabecular meshwork and cause peripheral anterior synechiae formation, progressively closing the anterior chamber angle and causing an intractable elevation of the intraocular pressure (IOP).

One important goal in management of neovascular glaucoma is treatment of retinal ischemia, reducing the stimulus for angiogenesis associated with the disorder. Panretinal photocoagulation (PRP) is an effective treatment for retinal ischemia and neovascularization of the anterior segment.¹²⁻¹⁸ When media clarity is poor, other treatments may be effective, including retinal cryotherapy,¹⁹⁻²¹ transscleral diode laser treatment,^{22,23} or endolaser.^{24,25} Treatment of underlying disease may improve neovascularization of the iris, as is the case with endarterectomy for carotid occlusive disease and ocular ischemia.²⁶ Eyes with proliferative diabetic retinopathy treated with PRP are less likely to develop rubeosis iridis after cataract surgery.⁹ Rubeosis iridis may regress and IOP may improve after treatment with PRP.²⁷ However, despite retinal ablative therapy, the IOP may remain elevated, most frequently in eyes with extensive synechial angle closure.²⁸

Another goal in management of neovascular glaucoma is control of IOP. If treatment of retinal ischemia alone is not effective, other treatments may be required to lower the IOP. When the anterior chamber angle is open, aqueous suppressants, topical corticosteroids, and cycloplegic drugs may be useful.²⁹ Cholinergic drugs are often ineffective and have been considered relatively contraindicated because they may increase inflammation. Similarly, because of concerns about hyperemia and inflammation, prostaglandin-related drugs should be used with caution. In eyes with neovascular glaucoma, use of antiangiogenesis drugs such as bevacizumab may enhance neovascular regression and reduce IOP.^{30,31} In patients with extensive synechial angle closure and marked elevation of the IOP, anti-vascular endothelial growth factor (anti-VEGF) drugs, aqueous suppressants and osmotic drugs (avoiding glycerol in diabetic patients), topical cycloplegic drugs, and corticosteroids may help prepare the eye for definitive surgical treatment.

High failure rates ranging up to 80% have been reported following trabeculectomy without antimetabolites for surgical treatment of neovascular glaucoma,^{32,33} presumably due to stimulus of angiogenesis and fibrovascular proliferation in the area around the bleb.³⁴ Adjunctive treatment with antifibrosis drugs such as mitomycin C and 5-fluorouracil have been associated with modest improvement of success,³⁵⁻⁴⁰ but neovascular glaucoma is still associated with declining success rates to as low as 28% at 5 years after surgery³⁵ and increased incidence of encapsulated bleb formation in treated eyes.³⁶ In comparison with other glaucoma diagnoses, neovascular glaucoma has been identified as a risk factor for failure of trabeculectomy.^{33,41} Glaucoma drainage implants are indicated when other surgical treatments have a poor prognosis for success, when prior conventional surgery has failed, or when significant conjunctival scarring precludes filtration surgery. Primarily because of the poor prognosis for success of trabeculectomy, glaucoma drainage implants have been used in the treatment of intractable elevation of IOP in neovascular glaucoma

From the Department of Ophthalmology, University of Virginia School of Medicine, Charlottesville.

SUCCESS AND FAILURE OF GLAUCOMA DRAINAGE IMPLANT SURGERY

Various risk factors for failure of trabeculectomy have been identified,^{41,42} which have clarified the role of trabeculectomy in the clinical management of glaucoma patients and prompted modifications of the procedure to improve clinical outcomes. In contrast with trabeculectomy, the variables that influence the prognosis for success of glaucoma drainage implant surgery are less well understood. The commonly used criteria for success for glaucoma drainage implant surgery include postoperative IOP (often greater than 5 mm Hg and less than 22 mm Hg) that is within a range close to the population-based normal range, without loss of vision, and without need for reoperation for glaucoma.⁴³

Current glaucoma drainage devices can be classified into two broad categories: flow-restrictive or non-flow-restrictive implants. Flow-restrictive, or valved, implants provide resistance to aqueous flow, which is intended to reduce the risk of hypotony during the early postoperative period. Non-flow-restrictive, or open tube drainage, implants provide little resistance to aqueous flow during the early postoperative period until a fibrous capsule forms around the plate. Various techniques have been devised for use during the early postoperative period to prevent hypotony associated with open tube implants. The Ahmed glaucoma valve and the Eagle Vision implant with a modified Krupin slit-valve are examples of flow-restrictive drainage devices. The non-flow-restrictive, or open tube drainage, implants include the Baerveldt glaucoma implant and the Molteno implant.

Increasing surface area for filtration by increasing plate size has been a strategy that has influenced designs of commercially available glaucoma drainage implants. In a study comparing different-sized Molteno implants, Heuer and colleagues⁴⁴ found significantly lower postoperative mean IOP and increased surgical success with the double-plate (270 mm²) compared with the single-plate (135 mm²) model. Similarly, the postoperative mean IOP was lower after double-plate compared with single-plate Molteno device implantation.⁴⁵ However, additional surface area does not considerably improve the results with larger implants, such as the Ahmed (184 mm²) and Baerveldt (250 mm² or 350 mm²) implants.⁴⁶⁻⁴⁹ These findings suggest a benefit of increasing surface area of the plate up to a point, beyond which there is little additional improvement of mean IOP or surgical success.

Additional IOP reduction and long-term success after glaucoma drainage implant surgery may be related to the degree of encapsulation around the implant plate, which provides resistance to aqueous flow.⁴³ In experimental studies, different plate materials may affect capsule formation and the results of glaucoma drainage implants.⁵⁰⁻⁵² In a prospective, randomized trial of 132 patients, the silicone (model FP7) compared with the polypropylene (model S2) Ahmed glaucoma valve showed differences in mean IOP, success rate, and complications, suggesting that plate material may influence clinical outcome.⁵³ In retrospective, comparative studies, similar differences have been found by some,^{54,55} but not all,^{56,57} investigators.

Very little information is available to allow direct comparisons of different glaucoma drainage implant plate designs. Retrospective studies of the Baerveldt and Ahmed glaucoma valve in similar patient populations found similar postoperative mean IOPs, number of medications, and surgical success rates.^{47,58} In a retrospective study,⁴⁶ the 350 mm² Baerveldt implant was compared to the double-plate Molteno implant, with similar mean IOP in short-term follow-up. The double-plate Molteno implant and the Ahmed glaucoma valve were retrospectively compared, with similar failure rates in the two groups.⁵⁹ In other retrospective studies, the Ahmed glaucoma valve was compared to the Baerveldt implant, with similar survival rates and IOP profiles in two studies^{60,61} and better survival and mean IOP after the Baerveldt 250 mm² compared with the Ahmed glaucoma valve in another study.⁶² In a systematic review of the literature,⁴³ no statistically significant differences were found in the postoperative mean IOP and success rate in comparing the Molteno implant, Baerveldt implant, Ahmed glaucoma valve, and Krupin valve. It is difficult to determine, at this time, whether there are differences in success rates with different implant designs, pending future direct comparisons of the implants.

Molteno and colleagues⁶³ suggested that a systemic antifibrosis regimen consisting of oral prednisone and flufenamic acid could improve the outcome of Molteno implants, but this was associated with systemic complications. In a prospective randomized trial evaluating the use of mitomycin C during Ahmed glaucoma valve implantation, Costa and colleagues⁶⁴ randomized 60 eyes of 60 patients to receive intraoperative mitomycin C or balanced salt solution, finding no difference in the success rates for both mitomycin C-treated eyes and controls. A prospective randomized trial of the Molteno implant found no difference in outcomes between 12 eyes treated with mitomycin C and 13 control eyes.⁶⁵ In retrospective comparative studies using the Molteno implant, one investigator found better IOP control in eyes that received intraoperative mitomycin C,⁶⁶ while another found no significant difference in outcomes between eyes treated with mitomycin C and controls.⁶⁷ In a retrospective study of eyes treated with the Baerveldt implant, there was no benefit of the intraoperative use of 5-fluorouracil or mitomycin C.⁶⁸ Intensive antifibrosis regimens of 5-fluorouracil and mitomycin C may improve the success rates of Ahmed glaucoma valve implantation.⁶⁹ However, standard doses used for adjunctive treatment of trabeculectomy appear to have little or no effect on the outcomes of glaucoma drainage implant surgery.⁷⁰

In addition to properties of the implant itself, patient-related variables could influence the outcomes of glaucoma drainage implant surgery. In a retrospective, comparative, case-control study of 86 eyes of 86 patients, Ishida and Netland⁷¹ found a greater risk of surgical failure after Ahmed glaucoma valve implantation in African American compared with Caucasian patients. In this study, Cox proportional hazards regression analysis detected African American race as a risk factor for failure of Ahmed glaucoma valve surgery. A noncomparative retrospective case series described results after single-plate Molteno implantation in black patients, reporting a 72% success rate, complicated by Tenon's cyst over the acrylic reservoir of single-plate Molteno device, which developed in 14 (88%) of 16 black patients without tenonectomy and 2 (3%) of 64 black patients with tenonectomy.⁷² Risk factors for failure have included African American descent and nonwhite race in retrospective studies of the Ahmed glaucoma valve and the Baerveldt implant.^{62,73,74}

The success of trabeculectomy is known to vary depending on the type of glaucoma,^{41,42} but there is less available information about the influence of glaucoma diagnosis on the outcomes of glaucoma drainage implant surgery. Glaucoma drainage implants may be used to treat intractable elevation of IOP in eyes with silicone oil tamponade, with implants placed in one of the inferior quadrants (inferior temporal or inferior nasal) to minimize loss of silicone oil through the tube or tube blockage.⁷⁵ In a retrospective comparative

study of 94 eyes in 94 patients, the Ahmed glaucoma valve controlled the IOP in the majority of eyes after pars plana vitrectomy and silicone oil injection.⁷⁶ However, the presence of silicone oil was associated with increased risk of surgical failure in eyes treated with the Ahmed glaucoma valve, with an odds ratio of 3.43.⁷⁶ Uveitic glaucoma has not been associated with increased risk of surgical failure after glaucoma drainage implant, particularly when uveitis is controlled through preoperative and long-term postoperative immunomodulatory therapy.^{77,78} Patients with severe ocular surface disease, who are often not candidates for trabeculectomy due to conjunctival scarring, may be successfully treated for elevated IOP with glaucoma drainage implant surgery.⁷⁹

In contrast with trabeculectomy, the location of the implant (superior vs inferior quadrant) does not affect the mean IOP or success rate after Ahmed glaucoma valve implantation.⁸⁰ Glaucoma drainage implants are used in patients at all stages of life, including pediatric patients.⁸¹ Unlike trabeculectomy, age has not been found to be a risk factor for failure of drainage implant surgery, except for one retrospective study of the Baerveldt and Molteno implants in pediatric patients,⁸² and another retrospective study of the Baerveldt implant in mixed ages.⁸³ Previous surgery has rarely been identified as a risk factor for failure of glaucoma drainage implant surgery,^{83,84} probably because a high proportion of patients in glaucoma drainage implant studies have had prior surgery or risk factors for failure of trabeculectomy. Implant-related and patient-related variables that may affect the success and failure risk profile of glaucoma drainage implant surgery are summarized in Table 1.

TABLE 1. VARIABLES INFLUENCING SUCCESS OF GLAUCOMA DRAINAGE IMPLANT SURGERY

VARIABLE	INFLUENCE SUCCESS OR FAILURE	LITTLE OR NO EFFECT ON SUCCESS OR FAILURE
Implant-related	Implant plate size Implant plate material	Adjunctive antifibrosis drugs Location of implant Superior vs inferior
Patient-related	Race Diagnosis Silicone oil endotamponade Neovascular glaucoma*	Age Previous surgery Diagnosis Controlled uveitis Severe ocular surface disease

* Present study.

PRESENT STUDY

The initial description of the use of glaucoma drainage implants in neovascular glaucoma was by Molteno and colleagues,⁸⁵ who described the technique for implantation and IOP results in 12 patients with an average of 13 months follow-up. Noncomparative retrospective studies have described results in patients with neovascular glaucoma after the Molteno implant,^{86,87} the Krupin implant,^{88,89} and the Baerveldt implant,^{74,90} with no control group for comparison. Previous studies have not used the Ahmed glaucoma valve and have not determined whether neovascular glaucoma patients have a poor prognosis for successful glaucoma drainage implant surgery compared with controls. The purpose of this study was to compare the outcomes of glaucoma drainage implant surgery using the Ahmed glaucoma valve in controls and in patients with neovascular glaucoma.

This study addressed the following questions:

1. Is the Ahmed glaucoma valve effective for lowering IOP in patients with neovascular glaucoma? If so, is it more or less effective compared with patients with other diagnoses treated with the Ahmed glaucoma valve?
2. Is the implant safe, and are there complications uniquely occurring in eyes with neovascular glaucoma?
3. Is there an increased risk of surgical failure in eyes with neovascular glaucoma compared with eyes with other diagnoses treated with the Ahmed glaucoma valve? How does this assessment contribute to our understanding of the risk profile of glaucoma drainage implant surgery?
4. In patients who lose vision, does IOP account for the vision loss?

METHODS AND PATIENTS

This was a single-center, retrospective comparative case series. The study was approved by the Institutional Review Board, consent was obtained prior to surgery in all patients, and the study was in accordance with Health Insurance Portability and Accountability Act (HIPAA) regulations. We reviewed the consecutive records of patients with neovascular glaucoma and control patients who were treated with the Ahmed glaucoma valve (New World Medical Inc, Rancho Cucamonga, California). All implantations were performed by one surgeon (P.A.N.) for increased IOP that was not responsive to medical therapy, laser treatment, or previous glaucoma surgery. Neovascular glaucoma, diagnosed by a glaucoma subspecialist (P.A.N.), was defined as neovascularization of the iris and/or anterior chamber angle with elevated IOP. Glaucomatous optic nerve cupping was not required for diagnosis.

Exclusion criteria included patient age less than 18 years old, previous cyclodestructive treatment, and previous glaucoma drainage

device implantation. Patients with less than 3 months follow-up were excluded from the analysis to allow evaluation of the results after the immediate postoperative period. Cases were matched to controls by age and sex, with both cases and controls chosen from the same time period. In patients with bilateral implantation, data analysis was performed for the first eye that had received surgery.

A total of 226 consecutive charts of patients treated with the Ahmed glaucoma valve were reviewed from a 6-year period. In 51 eyes with neovascular glaucoma treated with the Ahmed glaucoma valve, 7 eyes with less than 3 months follow-up were excluded from the analysis. In 6 patients with bilateral implantation, data analysis was performed for the first eye treated with the Ahmed glaucoma valve. Control eyes were not diagnosed with neovascularization of the anterior segment or neovascular glaucoma, did not meet exclusion criteria, and were age- and sex-matched to eyes with neovascular glaucoma. Thus, a total of 76 eyes of 76 patients were included in the analysis (38 eyes with neovascular glaucoma and 38 control eyes).

In eyes with neovascular glaucoma, all eyes had rubeosis iridis, and 89% of these eyes had closed angles by gonioscopy prior to glaucoma drainage implant surgery. All eyes with neovascular glaucoma had treatment with PRP or endolaser immediately before or after surgery. No eyes were treated with antiangiogenic drugs. Six eyes with neovascular glaucoma had been treated previously with pars plana vitrectomy and silicone oil injection. Three control eyes had a history of retinal detachment, requiring scleral buckling in 2 eyes. The majority of eyes (97%) received single-plate implants, with one eye in the controls and one eye in the neovascular glaucoma group treated with the double-plate Ahmed glaucoma valve. The majority of eyes in both groups (70 of 76 eyes, 92%) had been treated with the polypropylene plate (model S-2), while 6 of 76 (8%) had been treated with the silicone plate (model FP-7).

Preoperative information included gender, ethnicity, age, history of laser and surgical treatments, glaucoma diagnosis, lens status, glaucoma medications, IOP measured by Goldmann applanation tonometry, and visual acuity. Postoperative data regarding IOP, number of glaucoma medicines, visual acuity, and complications were obtained at 1 day, 1 week, 2 weeks, 1, 2, 3, 6, 12 months, and every 6 months thereafter. After the first month, visits within 2 weeks of the scheduled time point were included in the analysis. Results of the most recent examination were for analysis of IOP, visual acuity, and success at the last follow-up examination.

Criteria for success were defined before reviewing the data. Surgical success was defined as IOP of 6 mm Hg or greater and 21 mm Hg or less, with or without the use of additional glaucoma medicines, without further glaucoma surgery including cyclophotocoagulation or devastating complications that required removal of the implant, and without loss of light perception. No causes of vision loss were excluded, regardless of the etiology of decreased vision. The definition of hypotony was IOP of 5 mm Hg or less on two consecutive visits. A hypertensive phase was defined as IOP greater than 21 mm Hg during the first 3 to 6 months after surgery.

For Ahmed glaucoma valve implantation, a fornix-based conjunctival flap was created between the superior and lateral or the superior and medial rectus muscles. The tube of the Ahmed glaucoma valve was irrigated with balanced saline solution to prime the valve. The plate was secured 8 to 9 mm posterior to the surgical limbus with interrupted 9-0 nylon sutures. The tube was trimmed to extend approximately 3 mm beyond the surgical limbus with the bevel facing up and inserted in the anterior chamber through a 23-gauge needle track. The tube was anchored to the sclera using 9-0 nylon suture and covered with a rectangular piece of pericardium patch graft (IOP Inc, Costa Mesa, California, and New World Medical Inc, Rancho Cucamonga, California). The conjunctiva was closed with 9-0 polyglactin sutures, and subconjunctival injection of antibiotic and steroid was administered away from the surgical site.

Demographic and preoperative and postoperative data were compared between the control patients and patients with neovascular glaucoma. Mann-Whitney U tests were used to compare continuous parameters between the two groups. Wilcoxon signed rank test was used to compare continuous parameters within groups. Chi-square and Fisher exact tests were used for categorical variables. The cumulative probability of success was analyzed by the Kaplan-Meier life-table method. The log-rank test was used to compare the success rates calculated by life-table analysis. Cox proportional hazards regression models were performed to assess the relationship between survival outcomes and multiple predictors, including age, ethnicity, gender, diabetes mellitus, hypertension, preoperative IOP, glaucoma medications, preoperative number of surgeries, and preoperative visual acuity. Types of complications were compared using the comparison of proportions (z) test. P values of less than .05 were considered statistically significant.

RESULTS

A total of 76 eyes of 76 patients were analyzed in the study, including 38 eyes with neovascular glaucoma compared with 38 control eyes. In 6 patients with bilateral implantation, chart analysis was performed of the first eye that had received surgery. Seven eyes with less than 3 months follow-up were excluded from the analysis. Demographics and preoperative data are summarized in Table 2. The two groups were statistically comparable with respect to age, gender, race, presence of hypertension, lens status, and preoperative IOP ($P > .05$). Patients with neovascular glaucoma were significantly more likely than controls to have diabetes mellitus and to have a past history of surgery and laser treatment ($P < .05$). Patients with neovascular glaucoma were also more likely to use fewer glaucoma medications and have worse visual acuity compared with control patients ($P < .05$). The mean follow-up period was 18.4 ± 14.0 months (range, 3 to 60 months) in control eyes and 17.4 ± 15.1 months (range, 3 to 60 months) in neovascular glaucoma eyes ($P = .550$).

TABLE 2. AHMED GLAUCOMA VALVE IN NEOVASCULAR GLAUCOMA: PATIENT CHARACTERISTICS

CHARACTERISTIC	CONTROL N = 38 (100%)	NEOVASCULAR GLAUCOMA N = 38 (100%)	P VALUE
Age, yr (mean ± SD)	59.8 ± 17.5	54.2 ± 18.3	.271
Range, yr	18-90	18-89	
Gender, male/female, N (%)	19 (50.0)/19 (50.0)	19 (50.0)/19 (50.0)	>.999
Race, African American/Caucasian, N (%)	23 (60.5)/15 (39.5)	23 (60.5)/15 (39.5)	>.999
Eye, OD/OS, N (%)	13 (34.2)/25 (65.8)	18 (47.4)/20 (52.6)	.243
Follow-up, months (mean ± SD)	18.4 ± 14.0	17.4 ± 15.1	.550
Range, months	3-60	3-60	
Diabetes mellitus, N (%)	8 (21.1)	34 (89.5)	<.0001
Hypertension, N (%)	20 (55.6)	24 (63.2)	.353
Lens status, N (%)			.112
Phakic	11 (28.9)	12 (31.6)	
Aphakic	3 (7.9)	9 (23.7)	
Pseudophakic	24 (63.2)	17 (44.7)	
Previous surgery, N (%) *	38 (100)	27 (71.1)	.004
Number of procedures (mean ± SD)	1.9 ± 0.9	1.2 ± 1.0	.002
Range	1-5	0-4	
Previous laser therapy, N (%)	14 (36.8)	38 (100)	<.0001
Glaucoma diagnosis, N (%)			<.0001
POAG	15 (39.5)		
Glaucoma associated with PK	7 (21.0)		
Traumatic glaucoma	5 (14.0)		
CACG	3 (7.9)		
CMG	3 (7.9)		
Uveitic glaucoma	2 (5.3)		
Aniridia	1 (2.6)		
COAG	1 (2.6)		
Epithelial downgrowth	1 (2.6)		
Neovascular glaucoma	0 (0)	38 (100) [†]	
Preoperative IOP (mean ± SD), mm Hg	39.1 ± 11.2	43.8 ± 11.0	.065
Range, mm Hg	20-69	22-67	
Preoperative number medications (mean ± SD)	4.0 ± 0.9	3.3 ± 1.3	.013
Range	1-5	3-5	
Preoperative visual acuity, N (%)			.007
≥20/80	9 (23.7)	1 (2.6)	
<20/80-20/200	3 (7.9)	2 (5.3)	
<20/200-20/400	5 (13.1)	3 (7.9)	
<20/400-CF	10 (26.4)	6 (15.8)	
≤HM	11 (28.9)	26 (68.4)	

CACG, chronic angle-closure glaucoma; CF, count fingers; CMG, combined mechanism glaucoma; COAG, chronic open-angle glaucoma associated with multiple surgeries, including retinal detachment repair; HM, hand motion; IOP, intraocular pressure; PK, penetrating keratoplasty; POAG, primary open-angle glaucoma.

*Includes cataract surgery.

[†]Diagnoses in the neovascular glaucoma group included proliferative diabetic retinopathy (29 = 76%), central retinal vein occlusion (6 = 16%), central retinal artery occlusion (2 = 5%), and ocular ischemia (1 = 3%).

As shown in Table 3, the mean preoperative IOPs were 39.1 ± 11.2 mm Hg on an average of 4.0 ± 0.9 glaucoma medications for controls and 43.8 ± 11.0 mm Hg ($P = .065$) on an average of 3.3 ± 1.3 glaucoma medications ($P = .013$) in neovascular glaucoma patients. The mean IOPs at last follow-up were 16.2 ± 5.2 mm Hg in controls and 15.5 ± 12.5 mm Hg in neovascular glaucoma eyes ($P = .115$). The mean number of glaucoma medications at most recent follow-up was 1.5 ± 1.4 in controls and 0.7 ± 1.1 in neovascular glaucoma eyes ($P = .004$). At the most recent visit, the visual acuity was improved or within 1 Snellen line in 33 control eyes (86.8%)

and in 23 neovascular glaucoma eyes (60.5%) ($P = .018$). The success at last follow-up examination was significantly lower ($P = .032$) in neovascular glaucoma patients (63.2%, 24 of 38 eyes) compared with controls (86.8%, 33 of 38 eyes). At the last follow-up examination, significantly more ($P = .002$) eyes with neovascular glaucoma had lost light perception (23.7%, 9 of 38 eyes) compared with control eyes (0%, 0 of 38 eyes).

TABLE 3. AHMED GLAUCOMA VALVE IN NEOVASCULAR GLAUCOMA: PREOPERATIVE AND POSTOPERATIVE COMPARISONS

VARIABLE	CONTROL N = 38 (100%)	NEOVASCULAR GLAUCOMA N = 38 (100%)	P value
IOP (mm Hg; mean ± SD)			
Preoperative	39.1 ± 11.2	43.8 ± 11.0	.065
Postoperative	16.2 ± 5.2	15.5 ± 12.5	.115
Antiglaucoma medications (mm Hg; mean ± SD)			
Preoperative	4.0 ± 0.9	3.3 ± 1.3	.013
Postoperative	1.5 ± 1.4	0.7 ± 1.1	.004
Postoperative visual acuity			
Improved or within 1 Snellen line	33 (86.8)	23 (60.5)	.018
Worse by more than 1 Snellen line	5 (15.2)	15 (39.5)	
Hypertensive phase			
Within 3 months	17 (44.7)	13 (34.2)	.348
Within 6 months	17 (44.7)	14 (36.8)	.484
Surgical outcome			
Success	33 (86.8)	24 (63.2)	.032
Failure	5 (13.2)	14 (36.8)	
Loss of light perception	0 (0)	9 (23.7)	.002

IOP, intraocular pressure; SD, standard deviation.

At the last follow-up examination, the mean IOP was decreased significantly ($P < .001$) after drainage implant surgery in both controls and eyes with neovascular glaucoma (Figure 1). The mean number of medications was decreased significantly postoperatively compared with preoperatively in both groups ($P < .001$). A transient elevation of IOP (hypertensive phase) occurred within the first 3 months after surgery in 44.7% of controls (17 of 38 eyes) and 34.2% of eyes with neovascular glaucoma (13 of 38), which was not significantly different between groups ($P = .348$).

The mean preoperative IOP and the IOP at each of the postoperative time points are shown in Figure 2. The mean preoperative IOPs of 39.1 ± 11.2 mm Hg in control eyes and 43.8 ± 11.0 mm Hg in eyes with neovascular glaucoma ($P = .065$) were decreased to 17.9 ± 8.4 mm Hg and 16.5 ± 15.8 mm Hg at 1 year ($P = .150$), and to 17.2 ± 4.1 mm Hg and 4.3 ± 5.1 mm Hg at 3 years ($P = .028$), in controls and eyes with neovascular glaucoma, respectively. Although the majority of time points (12 of 16) were similar, the average IOP differences between two groups were statistically significantly different at postoperative day 1 ($P = .0007$), week 1 ($P = .038$), month 1 ($P = .007$), and year 3 ($P = .028$). After the initial reduction of IOP at postoperative day 1, the mean IOP gradually increased to a peak from 1 to 3 months, then gradually decreased, with a trend toward lower mean IOP at the later time points in the neovascular glaucoma compared with the control group.

Figure 3 shows the mean number of glaucoma medications preoperatively and at each of the postoperative time points. The mean preoperative number of medications of 4.0 ± 0.9 and 3.3 ± 1.3 ($P = .013$) was decreased to 1.7 ± 1.6 and 1.0 ± 1.3 at 1 year ($P = .166$), and 2.0 ± 1.7 and 0.7 ± 1.2 at 3 years ($P = .221$) in controls and eyes with neovascular glaucoma, respectively. In comparison to eyes with neovascular glaucoma, control eyes were using significantly more medications at 3 months after surgery ($P = .019$); however, this difference was not observed at subsequent time points. Both groups showed comparable trends, with a sharp reduction of the number of medications during the immediate postoperative period, a gradual increase during the first 2 to 3 years postoperatively, and a decreasing number of glaucoma medications thereafter.

The Kaplan-Meier survival analysis for success is shown in Figure 4. The cumulative probability of success for controls and eyes with neovascular glaucoma was 89.2% and 73.1% at 1 year, and 81.8% and 20.6% at 3 years, respectively. The difference of the survival curves between the two groups was statistically significant by log-rank test ($P = .0096$). The number of patients who had completed the follow-up period and were not classified as failures in the analysis of success in controls and eyes with neovascular glaucoma, respectively, was 31 and 26 at 1 year, 19 and 12 at 2 years, 11 and 7 at 3 years, and 6 and 5 at 4 years.

According to the definition of surgical success, 5 control eyes (13.2%) and 14 eyes with neovascular glaucoma (36.8%) were considered surgical failures. The majority of control eyes failed due to increased IOP (Table 4). In contrast, approximately half of the eyes with neovascular glaucoma were considered surgical failures due to hypotony (IOP ≤ 6 mm Hg). Although none of the control eyes lost light perception during the follow-up period, 9 eyes with neovascular glaucoma (23.7%) developed loss of light perception, with 4 of these meeting no other criteria for surgical failure. The majority of eyes with neovascular glaucoma and loss of vision (5 of

9) had IOP measurements of ≥ 6 mm Hg and ≤ 21 mm Hg during the postoperative period.

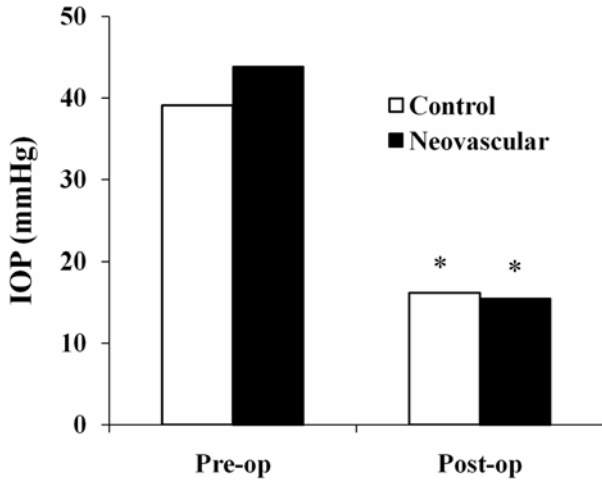


FIGURE 1

Comparison of preoperative and postoperative intraocular pressure (IOP) in controls and eyes with neovascular glaucoma. The postoperative IOP was the mean IOP at the last follow-up examination (mean follow-up period was 18.4 ± 14.0 months in controls and 17.4 ± 15.1 months in eyes with neovascular glaucoma). After Ahmed glaucoma valve surgery, the IOP was significantly lowered compared with the preoperative level ($P < .001$) for both control and neovascular glaucoma eyes. Asterisks indicate significant difference ($P < .05$) between the preoperative and postoperative IOP.

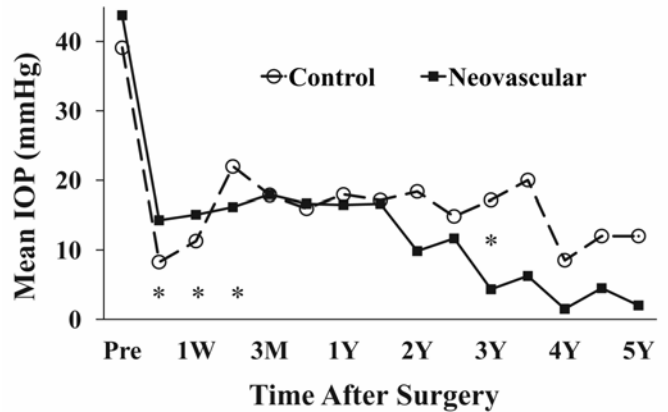


FIGURE 2

Mean intraocular pressure (IOP) after Ahmed glaucoma valve surgery in controls and eyes with neovascular glaucoma. The mean preoperative IOP of 39.1 ± 11.2 mm Hg and 43.8 ± 11.0 mm Hg ($P = .065$) was decreased to 17.9 ± 8.4 mm Hg and 16.5 ± 15.8 mm Hg at 1 year ($P = .150$), and 17.2 ± 4.1 mm Hg and 4.3 ± 5.1 mm Hg at 3 years ($P = .028$) in controls and eyes with neovascular glaucoma, respectively. Asterisks indicate significant differences ($P < .05$) between control and neovascular glaucoma eyes at individual time points. M, months; Pre, prior to surgery; W, week; Y, year(s).

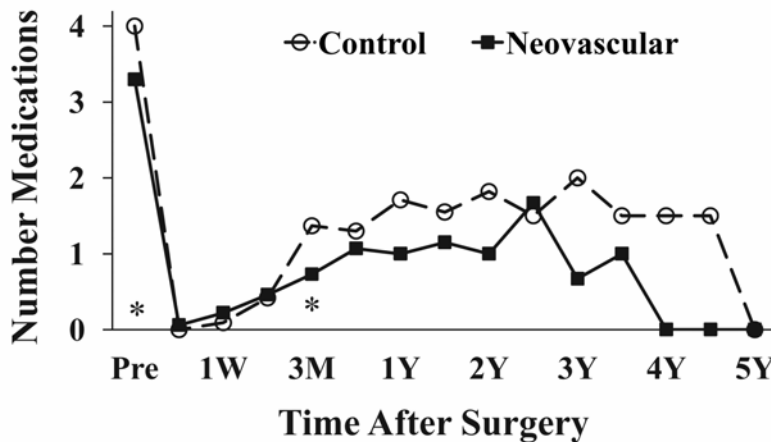


FIGURE 3

Average number of glaucoma medications after Ahmed glaucoma valve surgery in controls and eyes with neovascular glaucoma. The mean preoperative number of medications of 4.0 ± 0.9 and 3.3 ± 1.3 ($P = .013$) was decreased to 1.7 ± 1.6 and 1.0 ± 1.3 at 1 year ($P = .166$), and 2.0 ± 1.7 and 0.7 ± 1.2 at 3 years ($P = .221$) in controls and eyes with neovascular glaucoma, respectively. Asterisks indicate $P < .05$ (preoperatively and 3 months). M, months; Pre, prior to surgery; W, week; Y, year(s).

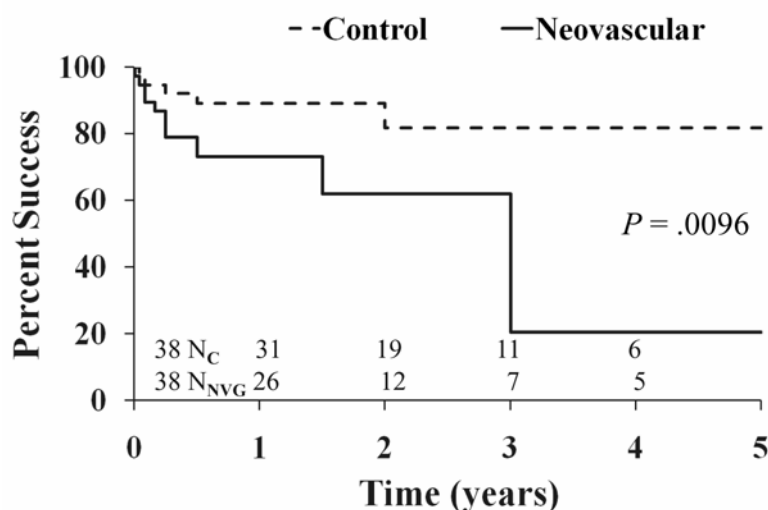


FIGURE 4

Cumulative probability of success after Ahmed glaucoma valve surgery in controls and eyes with neovascular glaucoma. The percent success for control and neovascular glaucoma eyes was 89.2% and 73.1% at 1 year, and 81.8% and 20.6% at 3 years, respectively. The difference of the survival curves between two groups was statistically significant by log-rank test ($P = .0096$). N_C , number of control eyes at time point; N_{NVG} , number of eyes with neovascular glaucoma at time point. Failures (5 control eyes, 14 neovascular glaucoma eyes) were carried forward in life-table analysis.

TABLE 4. AHMED GLAUCOMA VALVE IN NEOVASCULAR GLAUCOMA: REASONS FOR FAILURE OF GLAUCOMA DRAINAGE IMPLANT SURGERY*

REASON	CONTROL EYES N = 5	NEOVASCULAR GLAUCOMA EYES N = 14
IOP \geq 21 mm Hg	4 [†]	4 (1 lost LP)
IOP \leq 6 mm Hg	1	5 (3 lost LP)
Further glaucoma surgery	1 [†]	1 (1 lost LP)
Loss of LP	0	9 [‡]

IOP, intraocular pressure; LP, light perception.

*Reasons for failure add up to more than the number of failed eyes because some eyes had more than one criterion for failure.

[†]One of 4 eyes with IOP \geq 21 mm Hg treated with double-plate Ahmed glaucoma valve implantation.

[‡]Five of 9 eyes lost light perception with IOP \geq 5 mm Hg and \leq 21 mm Hg.

The characteristics of eyes classified as surgical successes or failures after drainage implant surgery are shown in Table 5. Neither successes nor failures in both groups were more likely to have had postoperative complications. In eyes with neovascular glaucoma, postoperative visual acuity was significantly decreased in failures compared to eyes with successful surgical outcome ($P = .035$). In the control group, failures had significantly higher IOP compared with successes ($P = .002$), whereas the IOP was not significantly different in eyes with neovascular glaucoma classified as success or failure ($P = .835$).

A Cox proportional hazards model was used to evaluate risk factors for surgical failure (Table 6). Factors analyzed included age, ethnicity, gender, neovascular glaucoma diagnosis, presence of diabetes mellitus or hypertension, preoperative IOP, number of preoperative glaucoma medications, preoperative visual acuity, and number of preoperative surgical treatments. Diagnosis of neovascular glaucoma was detected as a risk factor for surgical failure (odds ratio, 5.384; 95% CI, 1.22-23.84; $P = .027$), whereas other factors were not statistically significant risk factors for failure.

As shown in Table 7, complications occurred in 19 (50.0%) of 38 eyes in controls and 14 (36.8%) of 38 eyes with neovascular glaucoma after Ahmed glaucoma valve surgery. No statistically significant differences were detected between controls and eyes with neovascular glaucoma in comparisons of the number of eyes with complications ($P = .247$) or the average number of complications ($P = .135$). The most common complication in the eyes with neovascular glaucoma was hyphema, which occurred in 6 eyes (15.8%),

whereas the most frequent complication in control eyes was choroidal effusion (6 eyes, 15.8%). Obstruction of the tube occurred in 5 control eyes (13.2%) and 1 eye with neovascular glaucoma, most commonly due to fibrin during the immediate postoperative period. Other complications occurred infrequently, and implants were not removed in any of the patients.

TABLE 5. AHMED GLAUCOMA VALVE IN NEOVASCULAR GLAUCOMA: CHARACTERISTICS OF SUCCESSES AND FAILURES

CHARACTERISTIC	CONTROL N = 38 (100%)			NEOVASCULAR GLAUCOMA N = 38 (100%)		
	Success	Failure	P Value	Success	Failure	P value
Age, yr (mean ± SD)	59.5 ± 17.2	61.6 ± 17.5	.590	51.9 ± 16.8	58.0 ± 20.8	.164
Gender, N (%)						
Male	18 (47.4)	1 (2.6)	.597	14 (36.8)	5 (13.2)	.313
Female	16 (42.1)	3 (7.9)		10 (26.3)	9 (23.7)	
Lens status, N (%)						
Phakic	10 (26.3)	1 (2.6)	.406	9 (23.7)	3 (7.9)	.112
Aphakic	2 (5.3)	1 (2.6)		4 (10.5)	5 (13.2)	
Pseudophakic	22 (57.9)	2 (5.2)		11 (28.9)	6 (15.8)	
IOP (mean ± SD), mm Hg						
Preoperative	38.8 ± 11.6	41.0 ± 10.9	.397	44.8 ± 9.8	42.3 ± 13.0	.347
Postoperative	15.5 ± 3.06	21.6 ± 10.6	.002*	15.2 ± 3.6	15.9 ± 20.3	.835
Postoperative complications, N (%)	15 (39.5)	4 (10.5)	.113	8 (21.1)	6 (15.8)	.810
Postoperative visual acuity, N (%)						
Improved or within 1 line	22 (57.9)	2 (5.3)	.977	15 (39.5)	3 (7.9)	.035*
Worse by more than 1 Snellen line	12 (31.5)	2 (5.3)		9 (23.7)	11 (28.9)	

IOP, intraocular pressure.
*P<.05.

TABLE 6. AHMED GLAUCOMA VALVE IN NEOVASCULAR GLAUCOMA: OUTCOMES OF COX PROPORTIONAL HAZARDS REGRESSION MODEL FOR FAILURE OF DRAINAGE IMPLANT SURGERY

VARIABLE	ODDS RATIO	95% CONFIDENCE INTERVAL	P VALUE
Neovascular glaucoma	5.384	1.22-23.84	.027*
African American race	2.669	0.79-9.00	.113
Age	1.006	0.97-1.04	.723
Male gender	0.662	0.19-2.31	.518
Diabetes mellitus	1.975	0.50-7.84	.333
Hypertension	1.355	0.45-4.06	.588
Preoperative IOP	0.965	0.92-1.01	.162
Preoperative medications	0.717	0.46-1.13	.152
Preoperative surgery	0.774	0.13-4.68	.780
Preoperative visual acuity	0.366	0.10-1.01	.136

IOP, intraocular pressure.
*P<.05.

TABLE 7. AHMED GLAUCOMA VALVE IN NEOVASCULAR GLAUCOMA: POSTOPERATIVE COMPLICATIONS

VARIABLE	CONTROL (N = 38 EYES)	NEOVASCULAR GLAUCOMA (N = 38 EYES)	P VALUE*
Eyes with complications, N (%)			
Yes	19 (50)	14 (36.8)	.247
No	19 (50)	24 (63.2)	
Number complications, mean ± SD	1.08 ± 1.36	0.58 ± 0.89	.135
Type of complications [†]			
Hyphema	1 (2.6)	6 (15.8)	.111
Choroidal effusion	6 (15.8)	1 (2.6)	.111
Choroidal hemorrhage	2 (5.3)	3 (7.9)	.996
Inflammation	1 (2.6)	1 (2.6)	.471
Pupillary block	2 (5.3)	1 (2.6)	.988
Obstruction of tube	5 (13.2)	1 (2.6)	.198
By fibrin	3 (7.9)	1 (2.6)	.602
By iris	1 (2.6)	0 (0)	.990
By vitreous	1 (2.6)	0 (0)	.990
Retraction of tube	0 (0)	1 (2.6)	.990
Erosion of tube	2 (5.3)	1 (2.6)	.988
Corneal edema	3 (7.9)	1 (2.6)	.602
Tube-cornea touch	1 (2.6)	1 (2.6)	.471
Malignant glaucoma	2 (5.3)	1 (2.6)	.988

*Number of eyes with complications compared with chi-square, number of complications compared with *t* test, and types of complications compared with comparison of proportions (*z*) test.

[†]More than one complication may have occurred in one eye.

DISCUSSION

In addition to treatment of retinal ischemia, one of the therapeutic goals for neovascular glaucoma is reduction of IOP. Although neovascular glaucoma is a risk factor for failure of trabeculectomy,^{41,42} less is known about risk of failure after glaucoma drainage implant surgery. In this study, the success rate was significantly lower over time in eyes with neovascular glaucoma compared with controls, and neovascular glaucoma was a risk factor for failure of glaucoma drainage implant surgery. Despite significant improvement of IOP after Ahmed glaucoma valve surgery, visual outcomes were poor, with approximately one-quarter of patients losing vision.

In this study, the success at last follow-up visit in eyes with neovascular glaucoma and controls was significantly different, life-table analysis success rates were significantly different in the two groups, and Cox proportional hazards regression analysis identified neovascular glaucoma as a risk factor for failure of Ahmed glaucoma valve surgery. Results from the present study and noncomparative studies using other glaucoma drainage implants are summarized in Table 8.^{74,86-90} It is not possible to directly compare these other studies to the present study because of differences in implant types, patient populations, or other variables, and there was no control group for comparison. Nonetheless, the success rates reported in these studies are similar to the success rates reported in this study. The only study besides the present study with a comparison group was the study by WuDunn and colleagues,⁷⁴ in which a subgroup analysis of 34 eyes with neovascular glaucoma in a group of 108 eyes treated with the Baerveldt 250 mm² implant found neovascular glaucoma patients significantly more likely to fail due to elevated IOP. While a direct comparison of different implant types is not possible in this study, a retrospective review found no significant difference in mean IOP or cumulative probability of success after Ahmed glaucoma valve or Molteno implant in 65 eyes with neovascular glaucoma.⁹¹ The tabular summary (Table 8) does not include earlier published results from the same studies or preliminary results with implants that are no longer commercially available.⁹²⁻⁹⁴

Despite improvement of IOP after surgery and mean IOP levels over time that were comparable to controls, visual outcomes were worse, with significantly more eyes with neovascular glaucoma (9 of 38) than controls (0 of 38) losing light perception vision in this study (*P* = .002). This may have been due to inadequate control of IOP in eyes with neovascular glaucoma compared to controls, progression of underlying disease, or other factors. However, 5 of 9 eyes (55.6%) lost light perception with postoperative IOP above 5 mm Hg and less than 22 mm Hg, suggesting that progression of underlying disease is an important cause of vision loss in neovascular glaucoma. In previous studies (Table 8), the proportion of patients with neovascular glaucoma reported to lose vision has ranged from 3% up to 48%, with variability in vision loss rates possibly due to changes in retinal therapy over the time period of these studies, differences in patient populations including preoperative stage of neovascular glaucoma, or other variables. In neovascular glaucoma patients, the problem of vision loss has been observed after trabeculectomy. Parrish and Herschler⁹⁵ described 4 of 8 patients with

diabetic retinopathy or central retinal vein occlusion and neovascular glaucoma treated with a modified filtering procedure who lost ambulatory vision during the follow-up period, suggesting the importance of the underlying disease in preservation of visual function. Vision loss likely due to progression of underlying disease has also been observed following glaucoma drainage implant treatment for neovascular glaucoma patients.^{86,87,90}

TABLE 8. GLAUCOMA DRAINAGE IMPLANTS IN NEOVASCULAR GLAUCOMA: SUMMARY OF LITERATURE

STUDY	IMPLANT	N	MEAN FOLLOW-UP	SUCCESS DEFINITION*	PERCENT SUCCESS	PERCENT NLP
Present study						
NVG group	Ahmed	38	17.4 mo	6 mm Hg ≤ IOP ≤ 21 mm Hg Without additional surgery Without loss of vision	73.1% at 1 yr 61.9% at 2 yr 20.6% at 5 yr	23.7%
Control group	Ahmed	38	18.4 mo		89.2% at 1 yr 81.8% at 2 yr 81.8% at 5 yr	0%
Mermoud et al ⁸⁶	Molteno	60	24.7 m	IOP ≤ 21 mm Hg Without loss of vision	62.1% at 1 yr 52.9% at 2 yr 10.3% at 5 yr	48%
Every et al ⁸⁷	Molteno	145	39.6 mo	6 mm Hg ≤ IOP ≤ 21 mm Hg Without loss of vision	72% at 1 yr 60% at 2 yrs 40% at 5 yrs	32%
Krupin et al ⁸⁸	Krupin	79	23.7 mo	IOP ≤ 24 mm Hg	67.1% at last follow-up	19% of successes [‡]
Mastropasqua et al ⁸⁹	Krupin	28	58.4 mo	6 mm Hg ≤ IOP ≤ 21 mm Hg Without additional surgery No devastating complication	89% at 1 yr 74% at 2 yr 46% at 5 yrs	Not specified
Sidoti et al ⁹⁰	Baerveldt	36	15.7 mo	6 mm Hg ≤ IOP ≤ 21 mm Hg Without additional surgery No devastating complication	79% at 1 yr 38% at 2 yr	31%
WuDunn et al ⁷⁴	Baerveldt	34	14.1 mo [†]	6 mm Hg ≤ IOP ≤ 21 mm Hg Without additional surgery Without loss of vision	72% at 1.5 yr 16% at 5 yr	3%

IOP, intraocular pressure; NLP, no light perception; NVG, neovascular glaucoma.

*Loss of vision indicates loss of LP vision.

[†]Subgroup analysis.

[‡]Loss of vision data provided only for “successfully” treated eyes. Loss of LP in failures was not specified.

All of the patients in this study had anterior chamber tube placement and perioperative laser retinal therapy. In a retrospective noncomparative series, pars plana vitrectomy and glaucoma drainage implant tube placement was performed in a group of 40 eyes with mixed diagnoses (14 eyes with neovascular glaucoma), with a success rate (with or without glaucoma medications) of 72.5% at 1 year.⁹⁶ Although there was no comparison group, pars plana Ahmed glaucoma valve tube insertion with vitrectomy was performed in 18 eyes with neovascular glaucoma, with 72.2% overall success at an average 14.2 months follow-up.⁹⁷ Pars plana placement of Baerveldt implant tubes was compared with Nd:YAG cyclophotocoagulation in the management of neovascular glaucoma, with better control of IOP and greater preservation of vision after glaucoma drainage implant surgery.⁹⁸ Similar findings had been reported previously comparing anterior chamber placement of glaucoma drainage implant tubes with Nd:YAG cyclophotocoagulation.⁹⁹

In this study, the control group had a mean IOP of 16.2 mm Hg, 1.5 glaucoma medications, and 86.8% success rate at the last follow-up examination after Ahmed glaucoma valve surgery, with cumulative probability of success of 89.2% at 1 year and 81.8% at 2 to 5 years. In a study of 159 eyes with mixed diagnoses treated with the Ahmed glaucoma valve, Huang and colleagues⁵⁸ found a

mean IOP of 15.9 mm Hg, 1.1 glaucoma medications, and 84% success rate at the last follow-up examination. In a study that used a similar definition of success,⁷³ in 60 eyes with mixed diagnoses treated with the Ahmed glaucoma valve, the cumulative probability of success was 87% at 1 year, 82% at 2 years, and 76% at 3 to 4 years. Thus, the outcomes of the control group in this study were comparable to other studies assessing the response of refractory glaucomas with mixed diagnoses to treatment with the Ahmed glaucoma valve implant. Because the neovascular glaucoma patients in this study had a high percentage of patients with proliferative diabetic retinopathy (29 of 38, 76%), control eyes were less likely to have diabetes and prior laser or surgery in preoperative comparisons. Eyes with neovascular glaucoma were more likely to have poor vision preoperatively, probably due to differences in the extent and severity of retinal disease in eyes with neovascular glaucoma compared with controls. A significant difference was observed in the number of preoperative glaucoma medications in eyes with neovascular glaucoma and controls (3.3 ± 1.3 and 4.0 ± 0.9 , respectively), but this finding is not likely clinically relevant.

The mean postoperative IOP and number of medications during the follow-up period in this study were similar in controls and eyes with neovascular glaucoma, although a few individual time points were statistically significantly different. Nouri-Mandavi and Caprioli¹⁰⁰ reported that a hypertensive phase was observed in 56% of patients who had been treated with the Ahmed glaucoma valve. Ayyala and colleagues⁵⁹ noted that 84% of patients experienced a hypertensive phase after Ahmed glaucoma valve implantation. In this study, using a similar definition for hypertensive phase, 44.7% of controls and 34.3% of eyes with neovascular glaucoma developed a hypertensive phase within 3 months after Ahmed glaucoma valve implantation, which was not significantly different ($P = .348$). Neovascular glaucoma was identified as a risk factor for surgical failure by Cox proportional hazards regression analysis, while other variables did not achieve statistical significance. African American race, which has been identified as a risk factor for failure of Ahmed glaucoma valve surgery,⁷¹ was associated with an increased risk ratio that was not statistically significant in this study. This finding may have been due to lower statistical power (fewer African American patients) and a higher proportion of patients with neovascular glaucoma in this study compared with the previous study.⁷¹

The number of eyes with complications and the average number of complications were not significantly different between eyes with neovascular glaucoma and controls in this study. The most common complication in the neovascular glaucoma groups was hyphema, which was observed in 6 eyes (15.8%). In comparing eyes with neovascular glaucoma to controls, however, the difference was not statistically significant, probably due to a low number of individual complications available for statistical analysis. After Molteno device implantation in eyes with neovascular glaucoma, up to 65% incidence of transient hyphema during the early postoperative period has been reported.⁸⁷ The lower rate of hyphema in this study may have been due to differences of implant design (valved vs nonvalved), differences in the detection of hyphema, or differences in patient populations. In a retrospective noncomparative study of the Baerveldt implant in patients with mixed diagnoses, hyphema developed after implant surgery in 11 of 34 eyes (32%) with neovascular glaucoma.⁴⁷ In a subgroup analysis of eyes treated with the Baerveldt implant, hyphema was significantly more common during the postoperative period in eyes with neovascular glaucoma compared to eyes without neovascular glaucoma ($P = .02$).⁷⁴

Although this study is strengthened by the comparison group and case-control analysis, the nonrandomized retrospective design of this study has limitations. The average follow-up period was 17.4 ± 15.1 months in eyes with neovascular glaucoma, which was relatively short, despite efforts to contact patients directly or through their referring physicians. Other studies have found that patients with neovascular glaucoma treated with glaucoma surgery may be lost to follow-up due to comorbid conditions or death. The life expectancy of patients with neovascular glaucoma treated with Molteno implants was reduced by 52%.¹⁰¹ Every and colleagues⁸⁷ reported the deaths of 101 of 130 neovascular glaucoma patients (78%) during the follow-up period after treatment with the Molteno implant. During the follow-up period after treatment with the Krupin implant, 17 of 79 patients (22%) died in one study,⁸⁸ and 22 of 28 patients (79%) died in another study.⁸⁹ In this study, with the patients remaining in the analysis, valid life-table analysis was determined to 5 years. This study did not attempt to find the underlying cause for the differences in success observed in eyes with neovascular glaucoma and controls. However, this comparative study was able to identify significant differences in success rates over time in comparisons of controls and eyes with neovascular glaucoma.

SURGICAL TREATMENT OF NEOVASCULAR GLAUCOMA

Surgical treatment for neovascular glaucoma has evolved over time, from no treatment to cyclodestructive procedures, to full-thickness filtration surgery, and, finally, to trabeculectomy with antifibrosis drugs or glaucoma drainage implant surgery.³⁴ Neovascular glaucoma is a secondary glaucoma, which has numerous causes, and is a progressive disease over time. Prior to the onset of glaucoma, there may be neovascularization of the iris or angle, with normal IOP. In early stages of glaucoma, there is neovascularization of the angle, with an open anterior chamber angle and elevated IOP. In late stages of glaucoma, there is neovascularization of the angle, with a closed anterior chamber angle and markedly elevated IOP. Also, neovascular glaucoma is an inflammatory glaucoma, characterized by increasing inflammation of the anterior segment of the eye with continued disease progression. In addition to treatment of the underlying cause and treatment of retinal ischemia, surgical treatment for lowering IOP is often required, especially when there is synechial closure of the anterior chamber angle.

Several variables influence the choice of surgical treatment, which, most commonly, is a glaucoma drainage implant, a trabeculectomy with antifibrosis drug, or a cyclodestructive procedure. The stage of the disease may influence surgeons, with many favoring glaucoma drainage implants in more advanced disease. Similarly, the degree of inflammation may be a consideration, with glaucoma drainage implants preferred when severe inflammation is present, because of the poor prognosis of success of trabeculectomy with increased inflammation. The underlying etiology is relevant; for example, no surgical glaucoma therapy is indicated in an eye with neovascular glaucoma due to inadequately treated or untreated malignant ocular tumor. The vision or visual

potential is a consideration, with less invasive procedures such as cyclodestructive procedures preferred in eyes with limited or no visual potential. Moreover, comorbid conditions and life expectancy are influential, with less enthusiasm for surgical procedures in patients who have shortened life expectancy or severe comorbid medical conditions.

In retrospective studies, cyclophotocoagulation has been compared with glaucoma drainage implants for treatment of neovascular glaucoma, with better control of IOP and greater preservation of vision after glaucoma drainage implant surgery.^{98,99} In contrast, no significant difference in success rates was found after endoscopic diode cyclophotocoagulation compared with Ahmed glaucoma valve implantation in eyes with refractory glaucoma.¹⁰² In another study, there was no significant difference in the success rates comparing transscleral diode cyclophotocoagulation and Ahmed glaucoma valve implantation in neovascular glaucoma treatment, although lack of follow-up in the patients treated with cyclophotocoagulation (8 of 33 patients) limited the interpretation of results of the study.¹⁰³ In patients with uncontrolled IOP despite glaucoma drainage implant and glaucoma medical therapy, adjunctive diode cyclophotocoagulation significantly reduced mean IOP and the number of glaucoma medications in patients with refractory glaucoma, including neovascular glaucoma.¹⁰⁴

High failure rates ranging up to 80% have been reported following trabeculectomy without antimetabolites for surgical treatment of neovascular glaucoma,^{32,33} and neovascular glaucoma has been identified as a risk factor for failure of trabeculectomy.^{33,41} Adjunctive treatment with antifibrosis drugs such as mitomycin C and 5-fluorouracil have been associated with modest improvement of success,³⁵⁻⁴⁰ but neovascular glaucoma is still associated with declining success rates to as low as 28% at 5 years after surgery and encapsulated bleb formation.^{35,36} Because of the lack of direct comparative evidence in the literature, the choice between trabeculectomy and drainage implants is surgeon preference at this time. Considering the poor prognosis for success of trabeculectomy in neovascular glaucoma, surgeons often prefer glaucoma drainage implants, especially when patients with refractory neovascular glaucoma have increased inflammation at the time of surgery. Thus, retrospective analyses and comparative studies of glaucoma drainage implants and trabeculectomy have possible bias, with the possibility that surgeons would choose glaucoma drainage implants for more advanced disease.

Management of neovascular glaucoma varies and is individualized, depending on etiology, stage of disease, visual potential, and other variables. At the present time, glaucoma drainage implants are often used for lowering IOP in neovascular glaucoma patients. Results from this study support the role of drainage implants for lowering IOP in the treatment of neovascular glaucoma, although it is clear from the results of this study that patients may lose vision and may require adjunctive treatments. In addition to treatment of retinal ischemia and lowering of IOP, an additional goal of therapy of neovascular glaucoma worthy of consideration would be preservation of retinal and optic nerve function.

ANTIANGIOGENESIS TREATMENT IN NEOVASCULAR GLAUCOMA

Antiangiogenesis drugs have been swiftly incorporated into clinical management of neovascular glaucoma because they produce a rapid clinical response, reducing neovascularization of the anterior segment and decreasing anterior segment inflammation. Vascular endothelial growth factor is important in ocular abnormalities characterized by neovascularization, including neovascular glaucoma.¹⁰⁵⁻¹⁰⁷ Inhibiting angiogenesis by blocking VEGF activity is a promising strategy for the treatment of anterior segment neovascularization and neovascular glaucoma. One drug available for blocking VEGF is bevacizumab (Avastin, Genentech, Inc, San Francisco, California), which is a full-length humanized monoclonal antibody against VEGF type A.¹⁰⁵⁻¹⁰⁷

Several case reports have described clinical improvement, iris neovascularization regression, and IOP control following intravitreal bevacizumab injection.¹⁰⁸⁻¹¹⁷ In a noncomparative interventional case series study of 7 eyes in 5 patients, Oshima and colleagues¹¹⁸ observed regression of iris neovascularization in all treated patients, stable or improved visual acuity, and controlled IOP in 6 eyes during the follow-up period. In advanced neovascular glaucoma patients (with closed anterior chamber angle), noncomparative case studies have reported that bevacizumab may not control IOP but can be used adjunctively to improve results of subsequent glaucoma surgery.^{30,119}

In a retrospective comparative study of intravitreal bevacizumab with PRP vs PRP alone, the bevacizumab with PRP group experienced more rapid regression of neovascularization and decrease of IOP.³¹ In another retrospective comparative study of bevacizumab with PRP vs PRP alone, the bevacizumab-treated group had significantly improved visual outcomes and required significantly less glaucoma surgery, although addition of bevacizumab treatment did not reduce the need for glaucoma surgery in patients with closed anterior chamber angle.¹²⁰

Further studies are needed to establish the efficacy, safety, and clinical role of antiangiogenesis therapy for neovascular glaucoma. Results from the present study provide a basis for future work and highlight the need for further clinical research in this area. It would be of interest to determine whether antiangiogenesis therapy improves the success and prevents vision loss in neovascular glaucoma patients treated with glaucoma drainage implants.

CONCLUSION

This comparative study has identified significant differences in success rates over time in eyes with neovascular glaucoma and controls, indicating that neovascular glaucoma patients have a greater risk of surgical failure after Ahmed glaucoma valve surgery compared with patients with other glaucoma diagnoses. The significant treatment outcome difference found in this study indicates that neovascular glaucoma is a risk factor for failure of glaucoma drainage implant surgery. Despite improved mean IOP with the Ahmed glaucoma valve, visual outcomes were poor, possibly due to progression of the underlying disease. These findings improve the understanding of the risk profile for glaucoma drainage implant surgery, which may clarify the role of glaucoma drainage implants in the clinical management of neovascular glaucoma patients and may help direct efforts to improve clinical outcomes. In particular, in

neovascular glaucoma patients, the loss of vision despite lowering of average IOP by drainage implant surgery suggests the need for improved therapy to preserve function of the retina and optic nerve in the underlying conditions that cause neovascular glaucoma.

ACKNOWLEDGMENTS

Funding: None.

Financial Disclosures: None.

Conformity With Author Information: The study was approved by the University of Tennessee Health Science Center Institutional Review Board.

Other Acknowledgments: John W. Boyle IV, MD, and Kyoko Ishida, MD, contributed to the conduct of the study (collection, analysis, and interpretation of the data).

REFERENCES

1. Duke-Elder S. Glaucoma secondary to vascular diseases. Haemorrhagic glaucoma. In: Duke-Elder S, ed. *System of Ophthalmology, Volume XI: Diseases of the Lens and Vitreous, Glaucoma and Hypotony, Section III: Glaucoma and Hypotony*. St Louis: CV Mosby; 1969:667-677.
2. Weber PA. Neovascular glaucoma. Current management. *Surv Ophthalmol* 1981;26:149-153.
3. Hayreh SS. Neovascular glaucoma. *Prog Retinal Eye Res* 2007;26:470-485.
4. Sivak-Callcott JA, O'Day DM, Gass DM, Tsai JC. Evidence-based recommendations for the diagnosis and treatment of neovascular glaucoma. *Ophthalmology* 2001;108:1767-1778.
5. Brown GC, Magargal LE, Schachat A, Shah H. Neovascular glaucoma. Etiologic considerations. *Ophthalmology* 1984;91:315-320.
6. Casey R, Li WW. Factors controlling ocular angiogenesis. *Am J Ophthalmol* 1997;124:521-529.
7. Tripathi RC, Li J, Tripathi BJ, Chalam KV, Adamis AP. Increased level of vascular endothelial growth factor in aqueous humor of patients with neovascular glaucoma. *Ophthalmology* 1998;105:232-237.
8. Chen KH, Wu CC, Roy S, et al. Increased interleukin-6 in aqueous humor of neovascular glaucoma. *Invest Ophthalmol Vis Sci* 1999;40:2627-2632.
9. Aiello LM, Wand M, Liang G. Neovascular glaucoma and vitreous hemorrhage after cataract surgery in patients with diabetes mellitus. *Ophthalmology* 1983;90:814-820.
10. Rice TA, Michels RG, Maguire MG, Rice EF. The effect of lensectomy on the incidence of iris neovascularization and neovascular glaucoma after vitrectomy for diabetic retinopathy. *Am J Ophthalmol* 1983;95:1-11.
11. Weinreb RN, Wasserstrom JP, Parker W. Neovascular glaucoma following neodymium-YAG laser posterior capsulotomy. *Arch Ophthalmol* 1986;104:730-731.
12. Callahan MA. Photocoagulation and rubeosis iridis. *Am J Ophthalmol* 1974;78:873-874.
13. Wand M, Dueker DK, Aiello LM, Grant WM. Effects of panretinal photocoagulation on rubeosis iridis, angle neovascularization, and neovascular glaucoma. *Am J Ophthalmol* 1978;86:332-339.
14. Murphy RP, Egbert PR. Regression of iris neovascularization following panretinal photocoagulation. *Arch Ophthalmol* 1979;97:700-702.
15. Tasman W, Magargal LE, Augsburger JJ. Effects of argon laser photocoagulation on rubeosis iridis and angle neovascularization. *Ophthalmology* 1980;87:400-402.
16. Pavan PR, Folk JC, Wengeist TA, Hermsen VM, Watzke RC, Montague PR. Diabetic rubeosis and panretinal photocoagulation. A prospective, controlled masked trial using iris fluorescein angiography. *Arch Ophthalmol* 1983;101:882-884.
17. Magargal LE, Brown GC, Augsburger JJ, Donoso LA. Efficacy of panretinal photocoagulation in preventing neovascular glaucoma following ischemic central retinal vein obstruction. *Ophthalmology* 1982;89:780-784.
18. Hayreh SS, Klugman MR, Podhajskuy P, et al. Argon laser panretinal photocoagulation in ischemic central retinal vein occlusion. A 10-year prospective study. *Graefes Arch Clin Exp Ophthalmol* 1990;228:281-296.
19. Brodell LP, Olk RJ, Arribas NP, et al. Neovascular glaucoma: a retrospective analysis of treatment with peripheral panretinal cryotherapy. *Ophthalmic Surg* 1987;18:200-206.
20. Sihota R, Sandramouli S, Sood NN. A prospective evaluation of anterior retinal cryoablation in neovascular glaucoma. *Ophthalmic Surg* 1991;22:256-259.
21. Vernon SA, Cheng H. Panretinal cryotherapy in neovascular disease. *Br J Ophthalmol* 1988;72:401-405.
22. Tsai JC, Bloom PA, Franks WA, Khaw PT. Combined transscleral diode laser cyclophotocoagulation and transscleral retinal photocoagulation for refractory neovascular glaucoma. *Retina* 1996;16:164-166.
23. Flaxel CJ, Larkin GB, Broadway DB, Allen PJ, Leaver PK. Peripheral transscleral retinal diode laser for rubeosis iridis. *Retina* 1997;17:421-429.
24. Charles S. Endophotocoagulation. *Retina* 1981;1:117-120.
25. Bartz-Schmidt KU, Thumann G, Psichias A, Krieglstein GK, Heimann K. Pars plana vitrectomy, endolaser coagulation of the retina and the ciliary body combined with silicone oil endotamponade in the treatment of uncontrolled neovascular glaucoma. *Graefes Arch Clin Exp Ophthalmol* 1999;237:969-975.
26. Hayreh SS, Podhajskuy P. Ocular neovascularization with retinal vascular occlusion. *Arch Ophthalmol* 1982;100:1585-1596.

27. Ohnishi Y, Ishibashi T, Sagawa T. Fluorescein gonioangiography in diabetic neovascularisation. *Graefes Arch Clin Exp Ophthalmol* 1994;232:199-204.
28. Stefaniotou M, Paschides CA, Psilas K. Panretinal cryopexy for the management of neovascularization of the iris. *Ophthalmologica* 1995;209:141-144.
29. Ritch R, Barkana Y, Liebmann JM. Special therapeutic situations. In: Netland PA, ed. *Glaucoma Medical Therapy. Principles and Management*. New York: Oxford University Press; 2008:215-232.
30. Wakabayashi T, Oshima Y, Sakaguchi H, et al. Intravitreal bevacizumab to treat iris neovascularization and neovascular glaucoma secondary to ischemic retinal diseases in 41 consecutive cases. *Ophthalmology* 2008;115:1571-1580.
31. Ehlers JP, Spirn MJ, Lam A, Sivalingam A, Samuel MA, Tasman W. Combination intravitreal bevacizumab/panretinal photocoagulation versus panretinal photocoagulation alone in the treatment of neovascular glaucoma. *Retina* 2008;28:696-702.
32. Allen RC, Bellows AR, Hutchinson BT, Murphy SD. Filtration surgery in the treatment of neovascular glaucoma. *Ophthalmology* 1982;89:1181-1187.
33. Mietz H, Raschka B, Krieglstein GK. Risk factors for failures of trabeculectomies performed without antimetabolites. *Br J Ophthalmol* 1999;83:814-821.
34. Wand M. Neovascular glaucoma. In: Ritch R, Shields MB, Krupin T, eds. *The Glaucomas*. 2nd ed. St Louis: CV Mosby; 1996:1073-1129.
35. Tsai JC, Feuer WJ, Parrish RK II, Grajewski AL. 5-Fluorouracil filtering surgery and neovascular glaucoma. Long-term follow-up of the original pilot study. *Ophthalmology* 1995;102:887-892.
36. Katz GJ, Higginbotham EJ, Lichter PR, et al. Mitomycin C versus 5-fluorouracil in high-risk glaucoma filtering surgery. Extended follow-up. *Ophthalmology* 1995;102:1263-1269.
37. Kiuchi Y, Nakae K, Saito Y, Ito S, Ito N. Pars plana vitrectomy and panretinal photocoagulation combined with trabeculectomy for successful treatment of neovascular glaucoma. *Graefes Arch Clin Exp Ophthalmol* 2006;244:1627-1632.
38. Elgin U, Berker N, Batman A, Simsek T, Cankaya B. Trabeculectomy with mitomycin C combined with direct cauterization of peripheral iris in the management of neovascular glaucoma. *J Glaucoma* 2006;15:466-470.
39. Sisto D, Vetrugno M, Trabucco T, Cantatore F, Ruggeri G, Sborgia C. The role of antimetabolites in filtration surgery for neovascular glaucoma: intermediate-term follow-up. *Acta Ophthalmol Scand* 2007;85:267-271.
40. Al-Obeidan SA, Osman EA, Al-Amro SA, Kangave D, Abu El-Asrar AM. Full preoperative panretinal photocoagulation improves the outcome of trabeculectomy with mitomycin C for neovascular glaucoma. *Eur J Ophthalmol* 2008;18:758-764.
41. Borisuth NS, Phillips B, Krupin T. The risk profile of glaucoma filtration surgery. *Curr Opin Ophthalmol* 1999;10:112-116.
42. Katz LJ, Costa VP, Spaeth GL. Filtration surgery. In: Ritch R, Shields MB, Krupin T, eds. *The Glaucomas*. 2nd ed. St Louis: Mosby; 1996:1661-1702.
43. Hong C-H, Arosemena A, Zurakowski D, Ayyala RS. Glaucoma drainage devices: a systematic literature review and current controversies. *Surv Ophthalmol* 2005;50:48-60.
44. Heuer DK, Lloyd MA, Abrams DA, et al. Which is better? One or two? A randomized clinical trial of single-plate versus double-plate Moltano implantation for glaucomas in aphakia and pseudophakia. *Ophthalmology* 1992;99:1512-1519.
45. Broadway DC, Iester M, Schulzer M, Douglas GR. Survival analysis for success of Moltano tube implants. *Br J Ophthalmol* 2001;85:689-695.
46. Smith MF, Doyle JW, Sherwood MB. Comparison of the Baerveldt glaucoma implant with the double-plate Moltano drainage implant. *Arch Ophthalmol* 1995;113:444-447.
47. Siegner SW, Netland PA, Urban RC Jr, et al. Clinical experience with the Baerveldt glaucoma drainage implant. *Ophthalmology* 1995;102:1298-1307.
48. Britt MT, LaBree LD, Lloyd MA, et al. Randomized clinical trial of the 350-mm² versus the 500-mm² Baerveldt implant: longer term results. Is bigger better? *Ophthalmology* 1999;106:2312-2318.
49. Al-Aswad LA, Netland PA, Bellows AR, et al. Clinical experience with the double-plate Ahmed glaucoma valve. *Am J Ophthalmol* 2006;141:390-391.
50. Jacob JT, Burgoyne CF, McKinnon SJ, et al. Biocompatibility response to modified Baerveldt glaucoma drains. *J Biomed Mater Res* 1998;43:99-107.
51. Boswell CA, Noecker RJ, Mac M, et al. Evaluation of an aqueous drainage glaucoma device constructed of ePTFE. *J Biomed Mater Res* 1999;48:591-595.
52. Ayyala RS, Michelini-Norris B, Flores A, et al. Comparison of different biomaterials for glaucoma drainage devices: part 2. *Arch Ophthalmol* 2000;118:1081-1084.
53. Ishida K, Netland PA, Costa VP, Shiroma L, Khan B, Ahmed II. Comparison of polypropylene and silicone Ahmed glaucoma valves. *Ophthalmology* 2006;113:1320-1326.
54. Hinkle DM, Zurakowski D, Ayyala RS. A comparison of the polypropylene plate Ahmed glaucoma valve to the silicone plate Ahmed glaucoma flexible valve. *Eur J Ophthalmol* 2007;17:696-701.
55. Mackenzie PJ, Schertzer RM, Isbister CM. Comparison of silicone and polypropylene Ahmed glaucoma valves: two-year follow-up. *Can J Ophthalmol* 2007;42:227-232.
56. Law SK, Nguyen A, Coleman AL, Caprioli J. Comparison of safety and efficacy between silicone and polypropylene Ahmed glaucoma valves in refractory glaucoma. *Ophthalmology* 2005;112:1514-1520.

57. Brasil MV, Rockwood EJ, Smith SD. Comparison of silicone and polypropylene Ahmed glaucoma valve implants. *J Glaucoma* 2007;16:36-41.
58. Huang MC, Netland PA, Coleman AL, Siegner SW, Moster MR, Hill RA. Intermediate-term clinical experience with the Ahmed glaucoma valve implant. *Am J Ophthalmol* 1999;127:27-33.
59. Ayyala RS, Zurakowski D, Monshizadeh R, et al. Comparison of double-plate Molteno and Ahmed glaucoma valve in patients with advanced uncontrolled glaucoma. *Ophthalmic Surg Lasers* 2002;33:94-101.
60. Tsai JC, Johnson CC, Kammer JA, Dietrich MS. The Ahmed shunt versus the Baerveldt shunt for refractory glaucoma II: longer-term outcomes from a single surgeon. *Ophthalmology* 2006;113:913-917.
61. Syed HM, Law SK, Nam SH, Li G, Caprioli J, Coleman A. Baerveldt-350 implant versus Ahmed valve for refractory glaucoma: a case-controlled comparison. *J Glaucoma* 2004;13:38-45.
62. Goulet RJ 3rd, Phan AD, Cantor LB, WuDunn D. Efficacy of the Ahmed S2 glaucoma valve compared with the Baerveldt 250-mm² glaucoma implant. *Ophthalmology* 2008;115:1141-1147.
63. Molteno AC, Staughan JL, Ancker E. Control of bleb fibrosis after glaucoma surgery by anti-inflammatory agents. *S Afr Med J* 1976;50:881-885.
64. Costa VP, Azuara-Blanco A, Netland PA, Lesk MR, Arcieri ES. Efficacy and safety of adjunctive mitomycin C during Ahmed glaucoma valve implantation. A prospective randomized clinical trial. *Ophthalmology* 2004;111:1071-1076.
65. Cantor L, Burgoyne J, Sanders S, et al. The effect of mitomycin-C on Molteno implant surgery: a 1-year randomized, masked, prospective study. *J Glaucoma* 1998;7:240-246.
66. Perkins TW, Cardakli UF, Eisele JR, et al. Adjunctive mitomycin C in Molteno implant surgery. *Ophthalmology* 1995;102:91-97.
67. Lee D, Shin DH, Birt CM, et al. The effect of adjunctive mitomycin C in Molteno implant surgery. *Ophthalmology* 1997;104:2126-2135.
68. Tribble JR, Brown DB. Occlusive ligature and standardized fenestration of a Baerveldt with and without antimetabolites for early postoperative intraocular pressure control. *Ophthalmology* 1998;105:2243-2250.
69. Alvarado JA, Hollander DA, Juster RP, Lee LC. Ahmed valve implantation with adjunctive mitomycin C and 5-fluorouracil: long-term outcomes. *Am J Ophthalmol* 2008;146:276-284.
70. Minckler DS, Francis BA, Hodapp EA, et al. Aqueous shunts in glaucoma. A report by the American Academy of Ophthalmology. *Ophthalmology* 2008;115:1089-1098.
71. Ishida K, Netland PA. Ahmed glaucoma valve implantation in African American and white patients. *Arch Ophthalmol* 2006;124:800-806.
72. Freedman J, Rubin B. Molteno implant as a treatment for refractory glaucoma in black patients. *Arch Ophthalmol* 1991;108:1417-1420.
73. Topouzis F, Coleman AL, Choplin N, et al. Follow-up of the original cohort with the Ahmed glaucoma valve implant. *Am J Ophthalmol* 1999;128:198-204.
74. WuDunn D, Phan A-D, Cantor LB, Lind JT, Cortes A, Wu B. Clinical experience with the Baerveldt 250-mm² implant. *Ophthalmology* 2006;113:766-772.
75. Al-Jazzaf AM, Netland PA, Charles S. Incidence and management of elevated intraocular pressure after silicone oil injection. *J Glaucoma* 2005;14:40-46.
76. Ishida K, Ahmed IIK, Netland PA. Ahmed glaucoma valve surgical outcomes in eyes with and without silicone oil endotamponade. *J Glaucoma* 2009;18:325-330.
77. Netland PA, Denton NC. Uveitic glaucoma. *Contemp Ophthalmol* 2006;5:1-6.
78. DaMata A, Burk SE, Netland PA, Baltatzis S, Christen W, Foster CS. Management of uveitic glaucoma with Ahmed glaucoma valve implantation. *Ophthalmology* 1999;106:2168-2172.
79. Netland PA, Terada H, Dohlman CH. Glaucoma associated with keratoprosthesis. *Ophthalmology* 1998;105:751-757.
80. Rachmiel R, Trope GE, Buys YM, Flanagan JG, Chipman ML. Intermediate-term outcome and success of superior versus inferior Ahmed glaucoma valve implantation. *J Glaucoma* 2008;17:584-590.
81. Ishida K, Mandal AK, Netland PA. Glaucoma drainage implants in pediatric patients. *Ophthalmol Clin North Am* 2005;18:431-442.
82. Autrata R, Helmanova I, Oslejskova H, Vondracek P, Rehurek J. Glaucoma drainage implants in the treatment of refractory glaucoma in pediatric patients. *Eur J Ophthalmol* 2007;17:928-937.
83. Krishna R, Godfrey DG, Budenz DL, et al. Intermediate-term outcomes of 350-mm² Baerveldt glaucoma implants. *Ophthalmology* 2001;108:621-626.
84. Souza C, Tran DH, Loman J, Law SK, Coleman AL, Caprioli J. Long-term outcomes of Ahmed glaucoma valve implantation in refractory glaucomas. *Am J Ophthalmol* 2007;144:893-900.
85. Molteno AC, Van Rooyen MM, Bartholomew RS. Implants for draining neovascular glaucoma. *Br J Ophthalmol* 1977;61:120-125.
86. Mermoud A, Salmon JF, Alexander P, Straker C, Murray AD. Molteno tube implantation for neovascular glaucoma. Long-term results and factors influencing the outcome. *Ophthalmology* 1993;100:897-902.
87. Every SG, Molteno ACB, Bevin TH, Herbison P. Long-term results of Molteno implant insertion in cases of neovascular glaucoma. *Arch Ophthalmol* 2006;124:355-360.

88. Krupin T, Kaufman P, Mandell AI, et al. Long-term results of valve implants in filtering surgery for eyes with neovascular glaucoma. *Am J Ophthalmol* 1983;95:775-782.
89. Mastropasqua L, Carpineto P, Ciancaglini M, Zuppari E. Long-term results of Krupin-Denver valve implants in filtering surgery for neovascular glaucoma. *Ophthalmologica* 1996;210:203-206.
90. Sidoti PA, Dunphy TR, Baerveldt G, et al. Experience with the Baerveldt glaucoma implant in treating neovascular glaucoma. *Ophthalmology* 1995;102:1107-1118.
91. Yalvac IS, Eksioglu U, Satana B, Duman S. Long-term results of Ahmed glaucoma valve and Molteno implant in neovascular glaucoma. *Eye* 2007;21:65-70.
92. Krupin T, Kaufman P, Mandell A, et al. Filtering valve implant surgery for eyes with neovascular glaucoma. *Am J Ophthalmol* 1980;89:338-343.
93. Schocket SS, Lakhnpal V, Richards RD. Anterior chamber tube shunt to an encircling band in the treatment of neovascular glaucoma. *Ophthalmology* 1982;89:1188-1194.
94. Chihara E, Kubota H, Takanashi T, Nao-i N. Outcome of White pump shunt surgery for neovascular glaucoma in Asians. *Ophthalmic Surg* 1992;23:666-671.
95. Parrish R, Herschler J. Eyes with end-stage neovascular glaucoma. Natural history following successful modified filtering operation. *Arch Ophthalmol* 1983;101:745-746.
96. Scott IU, Alexandrakis G, Flynn HW Jr, et al. Combined pars plana vitrectomy and glaucoma drainage implant placement for refractory glaucoma. *Am J Ophthalmol* 2000;129:334-341.
97. Faghihi H, Hajizadeh F, Mohammadi SF, Kadkhoda A, Peyman GA, Riazi-Esfahani M. Pars plana Ahmed valve implant and vitrectomy in the management of neovascular glaucoma. *Ophthalmic Surg Lasers Imaging* 2007;38:292-300.
98. Chalam KV, Gandham S, Gupta S, Tripathi BJ, Tripathi RC. Pars plana modified Baerveldt implant versus neodymium:YAG cyclophotocoagulation in the management of neovascular glaucoma. *Ophthalmic Surg Lasers* 2002;33:383-393.
99. Eid TE, Katz LJ, Spaeth GL, Augsburger JJ. Tube-shunt surgery versus neodymium:YAG cyclophotocoagulation in the management of neovascular glaucoma. *Ophthalmology* 1997;104:1692-1700.
100. Nouri-Mandavi K, Caprioli J. Evaluation of the hypertensive phase after insertion of the Ahmed glaucoma valve. *Am J Ophthalmol* 2003;136:1001-1008.
101. Blanc JP, Molteno AC, Fuller JR, Bevin TH, Herbison P. Life expectancy of patients with neovascular glaucoma drained by Molteno implants. *Clin Experiment Ophthalmol* 2004;32:360-363.
102. Lima FE, Magacho L, Carvalho DM, Susanna R Jr, Avila MP. A prospective, comparative study between endoscopic cyclophotocoagulation and the Ahmed drainage implant in refractory glaucoma. *J Glaucoma* 2004;13:233-237.
103. Yildirim N, Yalvac IS, Sahin A, Ozer A, Bozca T. A comparative study between diode laser cyclophotocoagulation and the Ahmed glaucoma valve implant in neovascular glaucoma. A long-term follow-up. *J Glaucoma* 2009;18:192-196.
104. Samchyshyn TM, Tsai JC, Joos KM. Supplemental transscleral diode laser cyclophotocoagulation after aqueous shunt placement in refractory glaucoma. *Ophthalmology* 2002;109:1078-1084.
105. Andreoli CM, Miller JW. Anti-vascular endothelial growth factor therapy for ocular neovascular disease. *Curr Opin Ophthalmol* 2007;18:502-508.
106. Lynch SS, Cheng CM. Bevacizumab for neovascular ocular diseases. *Ann Pharmacother* 2007;41:614-625.
107. Bhisitkul RB. Vascular endothelial growth factor biology: clinical implications for ocular treatments. *Br J Ophthalmol* 2006;90:1542-1547.
108. Grisanti S, Biester S, Peters S, et al. Intracameral bevacizumab for iris rubeosis. *Am J Ophthalmol* 2006;142:158-160.
109. Iliiev ME, Domig D, Wolf-Schnurrbursch U, Wolk S, Sarra GM. Intravitreal bevacizumab (Avastin) in the treatment of neovascular glaucoma. *Am J Ophthalmol* 2006;142:1054-1056.
110. Mason JO 3rd, Albert MA Jr, Mays A, Vail R. Regression of neovascular iris vessels by intravitreal injection of bevacizumab. *Retina* 2006;26:839-841.
111. Kahook MY, Schuman JS, Noecker RJ. Intravitreal bevacizumab in a patient with neovascular glaucoma. *Ophthalmic Surg Lasers Imaging* 2006;37:144-146.
112. Chilov MN, Grigg JR, Playfair TJ. Bevacizumab (Avastin) for the treatment of neovascular glaucoma. *Clin Exp Ophthalmol* 2007;35:494-496.
113. Davidorf FH, Mourser JG, Derick RJ. Rapid improvement of rubeosis iridis from a single bevacizumab (Avastin) injection. *Retina* 2006;26:354-356.
114. Yazdani S, Hendi K, Pakravan M. Intravitreal bevacizumab (Avastin) injection for neovascular glaucoma. *J Glaucoma* 2007;16:437-439.
115. Vatavuk Z, Bencic G, Mandic Z. Intravitreal bevacizumab for neovascular glaucoma following central retinal artery occlusion. *Eur J Ophthalmol* 2007;17:269-271.
116. Costagliola C, Cipollone U, Rinaldi M, della Corte M, Semeraro F, Romano MR. Intravitreal bevacizumab (Avastin) injection for neovascular glaucoma: a survey on 23 cases throughout the 12-month follow-up. *Br J Clin Pharmacol* 2008;66:667-673.
117. Chalam KV, Gupta SK, Grover S, Brar VS, Agarwal S. Intracameral Avastin dramatically resolves iris neovascularization and reverses neovascular glaucoma. *Eur J Ophthalmol* 2008;18:255-262.
118. Oshima Y, Sakaguchi H, Gomi F, Tano Y. Regression of iris neovascularization after intravitreal injection of bevacizumab in patients with proliferative diabetic retinopathy. *Am J Ophthalmol* 2006;142:155-158.

119. Kitnarong N, Chindasub P, Metheetrairut A. Surgical outcome of intravitreal bevacizumab and filtration surgery in neovascular glaucoma. *Adv Ther* 2008;25:438-443.
120. Lupinacci APC, Calzada JI, Rafieetery M, Charles S, Netland PA. Clinical outcomes of patients with anterior segment neovascularization treated with or without intraocular bevacizumab. *Adv Ther* 2009;26:208-216.