

# MINI-TENOTOMY PROCEDURE TO CORRECT DIPLOPIA ASSOCIATED WITH SMALL-ANGLE STRABISMUS

BY **Kenneth W. Wright MD\***

## ABSTRACT

*Purpose:* The mini-tenotomy is a novel minimally invasive surgical technique that weakens rectus muscles to treat small-angle strabismus. The mini-tenotomy is an alternative to the standard rectus muscle recession that requires hooking the muscle, suturing the muscle, removing the muscle from sclera, and reattaching the muscle to sclera.

*Methods:* This is a retrospective chart review of outcomes of the mini-tenotomy procedure on 15 consecutive adult patients. A central tenotomy of 3 mm was performed cutting through intact conjunctiva using a blunt Westcott scissors.

*Results:* Preoperatively 6 patients were esotropic, measuring between 2 and 16 $\Delta$  (mean, 8 $\Delta$ ), and 9 patients had vertical deviations that measured between 2 and 6 $\Delta$  (mean, 3.5 $\Delta$ ).

Final postoperative esodeviations ranged from 1 to 8 $\Delta$  (mean, 5.8 $\Delta$ ), and hyperdeviations ranged from 0 to 4 $\Delta$  (mean, 1.3 $\Delta$ ). Final improvement of the deviation was larger for hypertropia, with a mean of 2.3 $\Delta$ , vs esotropia, with a mean of 1.3 $\Delta$ .

*Conclusion:* The mini-tenotomy is a safe and effective treatment for diplopia caused by a small-angle hypertropia or esotropia. It is a minimally invasive surgery that can be done in office with topical anesthesia. As with any strabismus procedure, more than one surgery may be necessary.

*Trans Am Ophthalmol Soc 2009;107:97-103*

## INTRODUCTION

Normal divergence and vertical fusion amplitudes are small, with divergence measuring 4 to 6 prism diopters ( $\Delta$ ) and vertical vergence less than 2 D.<sup>1</sup> Because of this, even small esodeviations and vertical deviations can cause significant asthenopic symptoms and diplopia, especially when the deviation is acquired in adulthood. Historically, these small-angle deviations have been treated with prism glasses. Prism spectacles are an excellent option if the patient is wearing spectacles for a refractive error, but for many patients prism spectacles are undesirable. Emmetropic patients, contact lens wearers, or postoperative refractive surgery patients generally do not consider prism spectacles an optimal treatment. Standard strabismus surgery, such as rectus muscle recession and resection, is designed to correct moderate to large-angle strabismus, usually greater than 10 $\Delta$ . Patients with strabismus less than 6 $\Delta$  to 8 $\Delta$  are not good surgical candidates because of the risk for overcorrection. This report introduces an alternative to standard strabismus surgery, a minimally invasive surgical procedure, a mini-tenotomy developed by the author. This procedure can be performed in the office with topical anesthesia and is specifically designed to correct diplopia associated with small-angle strabismus.

## METHODS

Charts from 15 consecutive patients who had undergone the mini-tenotomy procedure and had at least 1 month follow-up were reviewed. Mini-tenotomy was considered for the treatment of vertical deviations of 6 $\Delta$  or less and horizontal deviations of 16 $\Delta$  or less. The Internal Review Board of Cedars Sinai Medical Center approved the retrospective study, and patient confidentiality was maintained. The author performed the surgery in each case. Patients were examined by the author preoperatively and postoperatively. In two cases (patients 5 and 10), the last postoperative examination was done by the referring ophthalmologist.

The procedure was performed in the office using topical anesthetic with the patient fully awake and no sedation. Proparacaine, phenylephrine 2.5 %, and Vigamox drops were placed on the surgical eye prior to the surgery. Topical phenylephrine 2.5% was used to blanch the conjunctiva to facilitate visualization of the anterior ciliary vessels that come off the rectus muscle insertion. A cotton-tipped applicator soaked in proparacaine was placed on the conjunctiva overlying the surgical muscle for approximately 2 to 3 minutes. A lid speculum opened the eye. To expose the muscle, the patient was directed to look away from the surgical muscle. For example, if an inferior rectus was the surgical muscle, the patient was asked to look up, thus exposing the inferior rectus muscle. The anterior ciliary vessels of the surgical muscle were identified by direct visualization through intact conjunctiva.

With the conjunctiva intact, 3 to 4 mm of central muscle tendon was grasped with a 0.75 Wright tenotomy forceps (Titan Surgical, Los Angeles, California) at approximately 8 to 9 mm posterior to the limbus for the inferior rectus muscle and 7 to 8 mm posterior to the limbus for the medial rectus muscle (Figure 1). Care was taken to avoid grasping the anterior ciliary vessels. Once the rectus tendon was grasped, the forceps were gently moved side to side to see if the eye also moved, thus verifying that the tendon was grasped, rather than just superficial conjunctiva. After the central tendon was secured with the forceps, the tendon was gently pulled up off the globe and blunt Westcott scissors were used to cut the tendon between the forceps and sclera through the intact conjunctiva (Figure 2). After the central tenotomy, the tendon was released to fall back posteriorly (Figure 3). In some cases, if only 1 to 2 mm of tendon was initially cut, the tendon was re-grasped and the mini-tenotomy was repeated to obtain 3 to 4 mm of central tenotomy. The

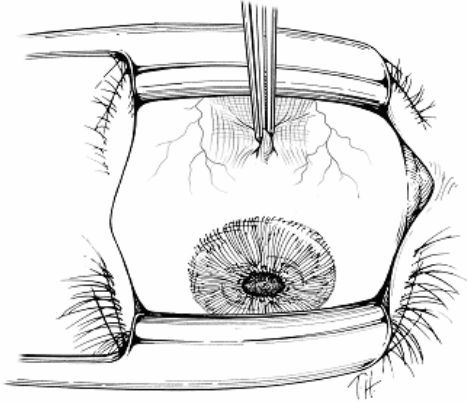
From the Wright Foundation for Pediatric Ophthalmology and Strabismus and the Department of Ophthalmology, University of Southern California—Keck School of Medicine, Los Angeles.

\*Presenter.

**Bold** type indicates AOS member.

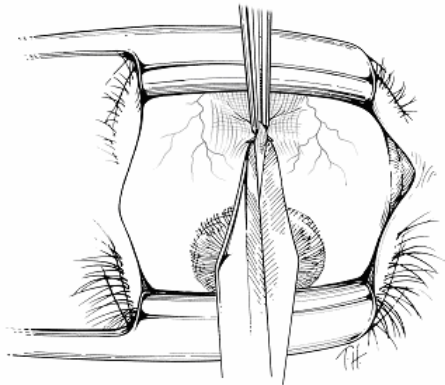
millimeters of central tenotomy were estimated by sight, not measured.

After the mini-tenotomy the patient was examined by cover test. If a residual deviation was present, the surgeon had the option to perform a mini-tenotomy of the fellow eye (ie, the antagonist of the yoke muscle to the operated muscle). At the end of the procedure, Vigamox drops were placed in the eye and the patient was sent home. A therapeutic regimen of either antibiotic corticosteroid ointment, two times a day for 3 days, or Vigamox drops, two times a day for 3 days, was begun.



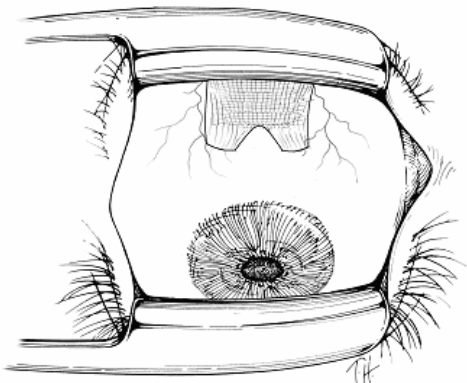
**FIGURE 1.**

After topical anesthetic is applied, the Wright 0.75-tooth tenotomy forceps grasp the central tendon of the rectus muscle through the intact conjunctiva



**FIGURE 2.**

Blunt Westcott scissors is used to cut the central tendon between the forceps and sclera through the intact conjunctiva.



**FIGURE 3.**

Postoperative drawing of the mini-tenotomy showing the central 3 to 4 mm of the tendon is cut. Note that the two muscle poles at the extremes of the insertion are left intact, maintaining the normally broad insertion.

## **RESULTS**

A summary of preoperative and postoperative details is shown in the Table. Patient ages ranged from 35 to 86 years, and 11 of 15 patients were 60 years or older. All 15 patients had binocular diplopia, and 5 of 15 were using prism glasses prior to surgery. Preoperatively 6 patients were esotropic, measuring between 2 and 16 $\Delta$  (mean, 8 $\Delta$ ), and 9 patients had vertical deviations that measured between 2 and 6 $\Delta$  (mean, 3.5 $\Delta$ ).

TABLE. DATA FOR 15 PATIENTS WHO UNDERWENT MINI-TENOTOMY

PATIENT NO.	AGE (yr)	DIAGNOSIS	PREOP DEV ( $\Delta$ )	MINI-T	POSTOP DEV ( $\Delta$ ) IMMEDIATE	CHANGE PER MINI-T ( $\Delta$ ) IMMEDIATE	POSTOP FINAL DEV ( $\Delta$ )	CHANGE PER MINI-T ( $\Delta$ ) FINAL	FOLLOW-UP (mo)	POST MINI-T DIPLOPIA
1	55	Retinal detachment Hypertropia	Right hypertropia 2	Left inferior rectus & 2nd mini-T @ 1 yr	0	2	0	2	13	Resolved
2	70	Divergence paresis Esotropia	Esotropia 16	Bilateral medial rectus	Esophoria 8	4	Esophoria 8	4	5	Improvement strabismus surgery
3	65	Divergence paresis Esotropia	Esophoria 4	Bilateral medial rectus	0	2	Esotropia 4	0	3	No improvement strabismus surgery
4	78	Congenital superior oblique palsy Hypertropia	Right hypertropia 5	L inferior rectus & 2nd mini-T Right superior rectus @ 3 wk	0	2.5	0	2.5	2	Resolved
5	49	Graves	Right hypertropia 2	Left inferior rectus	0	2	Right hypertropia 2	0	1	No improvement
6	73	Congenital superior oblique palsy Hypertropia	Right hypertropia 4	Right superior rectus with left inferior rectus	0	4	Right hypertropia 3	1	1	No improvement
7	73	Cataract surgery Hypertropia	Left hypertropia 4	Right inferior rectus	0	4	Right hypertropia 1	3	1	Resolved
8	86	Divergence paresis Esotropia	Esophoria 6	Bilateral medial rectus	Esophoria 1	3	Esophoria 6	0	11	No improvement prism
9	78	Divergence paresis Esotropia	Esotropia 10	Bilateral medial rectus	Esophoria 2	4	Esophoria 8	1	6	Improvement
10	35	Strabismus surgery Hypertropia	Right hypertropia 3	Left inferior rectus	0	3	Right hypertropia 3	0	1	No improvement
11	71	Trauma Esotropia	Esotropia 8	Bilateral medial rectus	Esophoria 2	3	Esophoria 8	0	4	No improvement, strabismus surgery

**TABLE (CONTINUED). DATA FOR 15 PATIENTS WHO UNDERWENT MINI-TENOTOMY**

PATIENT NO.	AGE (yr)	DIAGNOSIS	PREOP DEV ( $\Delta$ )	MINI-T	POSTOP DEV ( $\Delta$ ) IMMEDIATE	CHANGE PER MINI-T ( $\Delta$ ) IMMEDIATE	POSTOP FINAL DEV ( $\Delta$ )	CHANGE PER MINI-T ( $\Delta$ ) FINAL	FOLLOW-UP (mo)	POST MINI-T DIPLOPIA
12	78	Cataract surgery	Right hypertropia 2	Right superior rectus	0	2	Right hypertropia 1	1	12	Improvement
13	78	Cataract surgery	Esophoria 4	Bilateral medial rectus	0	2	Esophoria 1	1.5	4	Resolved
14	68	Strabismus surgery	Right hypertropia 4	Left inferior rectus & 2nd mini-T @ 6 wk	0	2	0	2	3	Resolved
15	52	Diplopia post refractive surgery	Right hypertropia 6	Right superior rectus	Right hypertropia 2	4	0	6	5	Resolved

Dev, deviation; Immed, immediately (day of surgery).

Final postoperative esodeviations ranged from 1 to 8 $\Delta$  (mean, 5.8 $\Delta$ ), and hyperdeviations ranged from 0 to 4 $\Delta$  (mean, 1.3 $\Delta$ ). Final improvement of the deviation was larger for hypertropia, with a mean of 2.3 $\Delta$ , vs esotropia, with a mean of 1.3 $\Delta$ . There seemed to be greater immediate improvement of the deviation (mean, 3.0 $\Delta$ ) as compared to the amount of improvement measured on the last follow-up visit (mean, 1.6 $\Delta$ ). Eight of the 15 patients (53%) were successfully treated with the mini-tenotomy procedure, improving the diplopia so no further treatment with prisms or standard strabismus surgery was necessary. Of 6 esotropic patients, 2 patients (33%) were successfully treated with the mini-tenotomy, whereas 3 required standard strabismus surgery and one was prescribed prism glasses. Hypertropia was successfully treated with the mini-tenotomy procedure in 6 of 9 patients (66%). Patients 1, 4, and 14 had a second mini-tenotomy in order to achieve success. In patients 1 and 14 the second procedure involved the previously tenotomized muscle, and in patient 4 it involved the muscle of the other eye.

Of 3 patients who subsequently had standard strabismus surgery, two had strabismus surgery on a rectus muscle that previously had a mini-tenotomy procedure. At the reoperation, there was minimal scarring and the central tendon was found to be adherent to sclera approximately 2 to 3 mm posterior to the original insertion. The previous mini-tenotomy procedure did not interfere with the standard strabismus surgery. There were no significant complications in any patient; however, 2 patients had a small self-limiting subconjunctival hemorrhage that resolved spontaneously, and one had blurred vision caused by topical anesthetic keratopathy that resolved spontaneously. Conjunctival scarring over the incision site was minimal. Each patient was asked if there had been pain or discomfort during the procedure. No patient experienced significant discomfort; however, 3 patients did not like the feeling of the lid speculum.

## DISCUSSION

Rectus muscle tenotomy is one of the first strabismus surgeries, described as early as the late 1800s.<sup>2</sup> In 1841 Reute described the tenotomy stating, "The tendon is cut without separating it from its surrounding tissue and the closer to its insertion the smaller the angle of strabismus."<sup>2</sup> Bohm modified the tenotomy in an attempt to avoid overcorrection, leaving the middle of the tendon intact (partial lateral tenotomy).<sup>2</sup> Tenotomy of rectus muscles was generally abandoned until Scott<sup>3</sup> reported graded rectus muscle tenotomy in 2006. This technique included subconjunctival injection of lidocaine and a conjunctival incision to expose the tendon. Over half the tendon was removed, starting at one pole, leaving one tendon pole attached to sclera, resulting in the cut tendon slanting back at an angle of 45°. Scott noted that a 60% to 70% tenotomy, or removing 6 to 7 mm of tendon, corrected approximately 4 $\Delta$  of strabismus. It is interesting that the prism diopters of correction per millimeter of tenotomy described by Scott is similar to the correction reported in the present study, where a 3- to 4-mm mini-tenotomy resulted in about 2 $\Delta$  of correction.

The slanted tenotomy reported by Scott effectively moves the insertion, thus changing the vector of muscle force and potentially inducing incomitance. Scott noted that in most cases this is not a practical issue; however, he did state that a "bothersome" vertical deviation could be induced if an upper tenotomy of one medial rectus muscle was performed along with a lower tenotomy on the contralateral medial rectus muscle. Likewise, an A pattern could theoretically be induced, or a V pattern treated, if the upper poles of both medial rectus muscles were removed, effectively moving the insertions down. This induced incomitance caused by the slanted pole tenotomy was substantiated by van der Muelen-Schot and associates.<sup>4</sup> In contrast to the slanted pole tenotomy, the mini-tenotomy described in this report is performed on the central tendon. The central tenotomy keeps the tendon poles intact so the normal wide rectus insertion is maintained, thus avoiding induced incomitance (Figure 3).

A central 3- to 4-mm tenotomy as described in this study releases approximately one-third of the insertion, as the rectus insertions are approximately 9 to 10 mm wide. The partial tenotomy produced a relatively small effect in most cases, correcting no more than 2 to 3  $\Delta$  of strabismus. A correction of up to 4 to 5 $\Delta$  can be obtained if binocular surgery is performed. For example, a right hypertropia of 4 $\Delta$  could be corrected by a right superior rectus tenotomy and left inferior rectus tenotomy. An esotropia of 4 to 6 $\Delta$  can be treated with bilateral medial rectus tenotomies. The mini-tenotomy described in this report is somewhat adjustable. One can operate on one muscle, then remeasure the deviation to determine if additional surgery is needed. Additionally, the size of the tenotomy can be enlarged by resnipping additional tendon fibers if a residual deviation is present. In patients in whom the mini-tenotomy fails to alleviate diplopia, standard surgery can be safely done without difficulty.

In some patients the deviation recurred several weeks to months after the mini-tenotomy procedure was done. This may be due to a larger phoria that was not disclosed preoperatively by standard alternate cover test, or it may be due to the scar contracture or muscle reorganization that occurs during the healing process. In this series there were no overcorrections, but several patients were undercorrected. Perhaps a larger tenotomy or posterior stripping of the tenotomized muscle might result in a greater correction.

Technically, the procedure is straightforward but does require facility with the extraocular muscles. The author prefers grasping the rectus tendon with Wright tenotomy forceps (0.75 mm) that have slightly blunt teeth and cutting the tendon with blunt Westcott scissors to avoid the unlikely occurrence of inadvertent scleral perforation. Using this technique, there were no significant complications. Transient blurred vision caused by topical anesthetic-induced keratopathy developed in one patient and resolved over 2 to 3 days, and two patients had a subconjunctival hemorrhage that was treated with direct pressure using a cotton-tipped applicator. The mini-tenotomy performed with topical anesthetic is almost painless. The only complaints were discomfort from insertion of the eyelid speculum. Grasping and cutting the central tendon did not cause pain in this series of patients.

The mini-tenotomy described in this report was found to be useful in treating diplopia in some patients with small-angle strabismus who did not want prism spectacles. It is a minimally invasive surgery that can be done in the office with topical anesthesia, and it provides an option to prism spectacles and standard strabismus surgery.

## ACKNOWLEDGMENTS

---

Funding/Support: This study was supported by the Wright Foundation for Pediatric Ophthalmology and Strabismus.

Financial Disclosures: Dr Wright receives a royalty on a surgical instrument manufactured by Titan Surgical LLC but does not receive royalty from instruments discussed in this article.

Conformity With Author Information: The Internal Review Board from Cedars Sinai Medical Center approved the retrospective study, and patient confidentiality was maintained.

## REFERENCES

---

1. Wright KW, Spiegel P. Binocular vision and introduction to strabismus. In: *Pediatric Ophthalmology and Strabismus, 2nd ed.* New York: Springer-Verlag; 2002:155.
2. von Noorden GK, ed. Strabismology from its beginnings to the middle of the 19th century. In: *The History of Strabismology.* Oostende, Belgium: J.P. Wayenborgh; 2002:41-46.
3. Scott AB. Graded rectus muscle tenotomy. *Arch Chil Oftal* 2006;63:127-128.
4. van der Muelen-Schot HM, van der Muelen-Schot SB, Simonsz HJ. Caudal or cranial partial tenotomy of the horizontal rectus muscles in A and V pattern strabismus. *Br J Ophthalmol* 2008;92:245-251.

## PEER DISCUSSION

---

JAMES D. REYNOLDS MD: Small angle strabismus with diplopia can be frustrating for patient and surgeon alike. This is true of primary deviations and unfortunately even truer in postoperative patients. It is one of the ironies of adult strabismus surgery that dramatically improving appearance can lead to worse function. By that I mean that diplopia resulting from 30-50 prism diopters is often ignorable, but that resulting from 5 prism diopters can be disabling.

There are several management options, none of which work well in many patients. Prisms can be effective, but some patients are intolerant of these, often for ill-defined reasons. Occlusion, e.g. Bangerter filter, has obvious disadvantages. Self guided coping mechanisms are utilized by many by default but are only a last resort for the ophthalmologist, which brings us to surgery. Unfortunately, small angle strabismus is prone to over correction when using standard recess/resect procedures. This is why alternative surgical approaches have appeal.

Partial thickness tenotomies or myotomies have been utilized for over 150 years.<sup>1</sup> A common practice today is marginal myotomy, usually used in conjunction with an antagonist resection for standard sized deviations. Such a marginal myotomy is often performed as a Z-plasty type incision across one third to one half the tendon width. Its use is often restricted to already dramatically recessed muscles where re-recession is not prudent.

The use of partial thickness tenotomy as a primary procedure unaccompanied by a resection has been used for small angle strabismus to improve diplopia, both initially or in reoperations. Its recent awareness has been heightened by Scott<sup>2,3</sup> and Biglan<sup>4</sup> and now as altered by Wright. In 2000 and 2006, Scott described an insertional vertical rectus muscle tenotomy, performed on one edge of the insertion, and graded by progressively enlarging the incision and correlating with the result. Biglan and co-workers did the same in 2004 on vertical muscles only. This is essentially a sutureless, adjustable strabismus surgery with the adjustment being intraoperative.

Criticisms of this include the unavoidable vertical or horizontal insertion offsets, the induction of small incomitancies, such as A or V patterns, and the technical difficulties of the progressive adjustments under local or intravenous sedation. Wright's modification avoids these difficulties. Wright's technique is unique in that it is performed in the office under only topical anesthesia and its central tendon incision avoids the slanting insertion result of Scott and Biglan. It is also readily adjustable by repeating on the same or a different muscle contemporaneously.

Are these procedures useful? The three groups all report success, although to varying degrees. This is not surprising. Clearly they are muscle weakening procedures. However, that weakening effect is limited, but that is precisely the point. So, the key to success is likely patient selection.

Wright selects both vertical and horizontal strabismus. His angle size varies from 2-16 prism diopters. (Vertical  $\leq$  6 PD; Horizontal  $\leq$  16 PD) His angle character includes both phorias and tropias, the former presumably suffering intermittent diplopia. When assessing Wright's results it is apparent that patient selection is indeed critical. His largest horizontal deviations (ET 8, 10, and 16) were not successful. Two required standard strabismus surgery and the ET 10 was improved to an E 8. It is reasonable to assume these patients should have had conventional recessions in the first place. Assessing angle type selection, six patients had horizontal angles, all esodeviations. Three are mentioned above. The other three were E 4, E 6, and E 4. Two of these showed no improvement. Only one was resolved. The final way to analyze patient selection is angle character. None of his tropias were successful. Only his phorias, presumably intermittent, were successful. This is also a critical factor.

So, the key to success is careful patient selection. This analysis would suggest the following eligibility criteria:

1. Angle type – vertical strabismus
2. Angle size – less than or equal to 6 PD
3. Angle character – phorias or intermittent tropias

Applying these selection criteria Wright had complete success i.e. resolution in 5 of 9 (55%). Outside these selection criteria, Wright had complete success in 1 of 6 (17%). It should be noted that three of his six complete successes required two separate mini-tenotomies.

Finally, two technical issues were unclear. Wright specifies the distance from the limbus at which he grasps the muscle. He does not specify the incision point. It is anterior and can we assume at the insertion? Also three of his mini-tenotomy failures went on to conventional surgery. Two were larger deviations (ET 8 and ET 10) and so are understandable. But the remaining one was an E 4 that became an ET 4. What made this small deviation amenable to conventional strabismus surgery?

Dr. Wright is to be commended for bringing his creativity to a thorny problem. Given adequate patient selection, this procedure can be a useful addition to a strabismus surgeon's repertoire.

## ACKNOWLEDGEMENTS

Funding/Support: None

Conflict of Interest: None

## REFERENCES

---

1. Howe L. Partial Tenotomy. In: Howe L. ed. *The Muscles of the Eye*. London/New York: GP Putnam's Sons/The Knickerbocker Press 1908:304-308.
2. Scott AB. Graded rectus muscle tenotomy for small deviations. In: *Proceedings of the Jampolasky Festschrift*. San Francisco: The Smith-Kettlewell Eye Research Institute; 2000:215-216.
3. Scott AB, Graded rectus muscle tenotomy. *Arch Chil Oftal* 2006; 63:127-128.
4. Yim HB, Biglan AW, Cronin, TH. Graded partial tenotomy of vertical rectus muscles for treatment of hypertropia. *Trans Am Ophthalmol Soc* 2004;102:169-176.

DR. MARIAN S. MACSAI: Did you measure the vertical fusional amplitudes before doing the procedure and does that matter?

DR. IRENE LUDWIG: I have a third variant of this operation that I performed for several years that has also been very useful. I perform multiple myotomies at staggered intervals in the fibrotic tissues in the muscle and that results in a 2 prism diopter effect. I would also like to suggest that with some patients who have gradually, very slowly progressing angles of esodeviation, some of them may be due to the pulley collapse if they are elderly, as Joe Demer has described. A fair number have adjacent sinus disease and if you do not recognize it and treat it, then deviation will recur. Sometimes a referral to the ear, nose and throat specialist can prevent the gradual recurrence of this small angle esodeviation or the hypodeviations.

DR. ARTHUR JAMPOLSKY: No commercial interest. The discussion brought up the salient difference between selected patients of vertical versus horizontal small deviations. I would suggest that the example of the patient with vertical deviation was post-surgery, and probably had a fusion potential. Any surgery one does on an old long-standing decompensated esotropia, especially with a small angle of deviation, may go right back from whence it came. I was also interested in the discussion of pre-modern, and then modern era in the 2000s, but what was skipped over was the important 1940s-50s. A half century ago in California, it was very common for a central tenotomy of the medial rectus to be performed and to be opposed by an O'Connor cinch of the lateral rectus for esotropias. There were many reports of repeating a central tenotomy on one previously done, had the frequent complication of completely cutting off one edge of the central tenotomy, which was not quite as central as it was supposed to be.

DR. BRONWYN BATEMAN: No conflicts of interest. I congratulate you, Ken, for thinking outside the box. I have one suggestion that you might try and it does not involve using the Wescott scissors. It would be very useful to do a good forced duction test on these patients and have them stand up and see if the double vision has gone away with just that procedure. Pulling on the inferior rectus may have some effect of decreasing a very small deviation.

DR. KENNETH W. WRIGHT: I want to thank the Jim Reynolds for his discussion. This procedure was developed as an alternative to prism glasses to treat diplopia from small angle strabismus. We did not perform formal measurement of vertical fusion amplitudes, but did perform prism neutralization to help determine the angle of strabismus for both esotropia and hypertropia patients. I do not find vertical fusional amplitudes to be particularly helpful. Large vertical amplitudes can be present, yet if the deviation is poorly controlled and the patient is symptomatic, then surgery is still required. The amount of surgery is not determined by the fusion amplitudes as the target angle is based on the full deviation measured by prism cover test. A recurrent deviation occurs after surgery as a latent deviation becomes manifest after surgery much like prisms that need to be increased soon after prism glasses are prescribed.

The issue regarding central versus marginal tenotomy was raised. I like the central approach because it avoids the ciliary vessels. The anterior ciliary vessels course on the lateral aspect of the muscle so the central tenotomy avoids those vessels. The central tenotomy also provides stability as the muscle poles are left intact. Thank you.