

POLYCHROMASIA CAPSULARE (MULTICOLORED CAPSULE): REPORT OF THREE FAMILIES

BY **Elias I. Traboulsi MD**,* Daniel Chung DO, AND John M. Koors MD

ABSTRACT

Purpose: To describe the familial occurrence of a peripheral ring of anterior lens capsule discoloration and iridescence in three families.

Methods: Clinical ophthalmologic examination with visual acuity, slit-lamp biomicroscopy, and dilated ophthalmoscopy. Pedigree construction and evaluation for possible mode(s) of inheritance.

Results: In family 1, 25 members from four generations were available for examination. Twelve had identical findings consisting of a peripheral circumferential polychromatic band of anterior lens capsule. The band was predominantly iridescent green but exhibited a rainbow of colors on direct illumination with the slit-lamp beam. There were affected individuals in all four generations. The proband, one of her sons, and her granddaughter had no clinical, serologic, or other laboratory evidence of Wilson's disease, hypercupremia, or myotonic dystrophy. In family 2, three individuals in three generations were similarly affected. In family 3, a man and his son and daughter had identical peripheral lens capsule discoloration.

Conclusions: *Polychromasia capsularis* is a rare benign autosomal dominant ocular trait that does not appear to be associated with ophthalmologic or systemic disease. The occurrence in consecutive generations and the presence of male-to-male transmission are consistent with autosomal dominant inheritance.

Trans Am Ophthalmol Soc 2005;103:93-97

INTRODUCTION

A syndrome of "hereditary tinted lenses" was described very briefly in two families in a one-page communication in volume V of *Birth Defects Original Article Series* in 1969.¹ Five members of one family had a greenish blue color of the peripheral anterior capsule of both lenses. The discoloration was present in the entire circumference and appeared to lie within or slightly beneath the lens capsule. The proband's physical examination was otherwise normal, and ceruloplasmin levels were normal. A woman and her two sons in another family were similarly affected. We were unable to find other descriptions of this condition in the literature since 1969.

We present three families with identical lens capsule findings and autosomal dominant inheritance.

FAMILY REPORTS

Family 1

The 52-year-old proband was referred because the peripheral lens capsule was "green." Her vision had been reduced for a number of years. She had received laser treatment for a macular neovascular lesion 2 years previously. Wilson's disease had been ruled out by the appropriate tests. There were no signs or symptoms suggestive of myotonic dystrophy. Her past medical history was significant for back problems, arthritis, and three episodes of Bell's palsy. She was HLA-B27 positive. Several family members had been diagnosed as having "colored lens opacities." Visual acuity was 20/40 OD and 20/25 OS. She had active anterior uveitis that responded subsequently to topical steroid therapy. A complete ring of peripheral anterior lens capsule discoloration was visualized with the slit lamp after pupillary dilation (Figure 1). Ophthalmoscopy revealed central macular scars in both eyes with a few fine peripheral round scars compatible with a diagnosis of presumed ocular histoplasmosis.

A family reunion was organized in which all available family members were examined (Figure 2A). The proband's affected granddaughter, who was 7.5 years old, also underwent examination for Wilson's disease, and the laboratory tests were negative. The youngest examined affected family member was a boy 3.5 years of age; the proband was the oldest. The slit-lamp findings were identical in all affected individuals, and there was no evidence of increase in density or change in color with increasing age. No other ocular abnormalities were present in any of the affected individuals.

Families 2 and 3

The table summarizes the ocular findings in these two families. (See also Figures 2B and 2C for the pedigrees of these two families).

From the Center for Genetic Eye Diseases, Cole Eye Institute, Cleveland Clinic Foundation, Cleveland, Ohio (Dr Traboulsi, Dr Chung), and the East Alabama Eye Clinic, Anniston, Alabama (Dr Koors).

*Presenter.

Bold type indicates **proband** member.

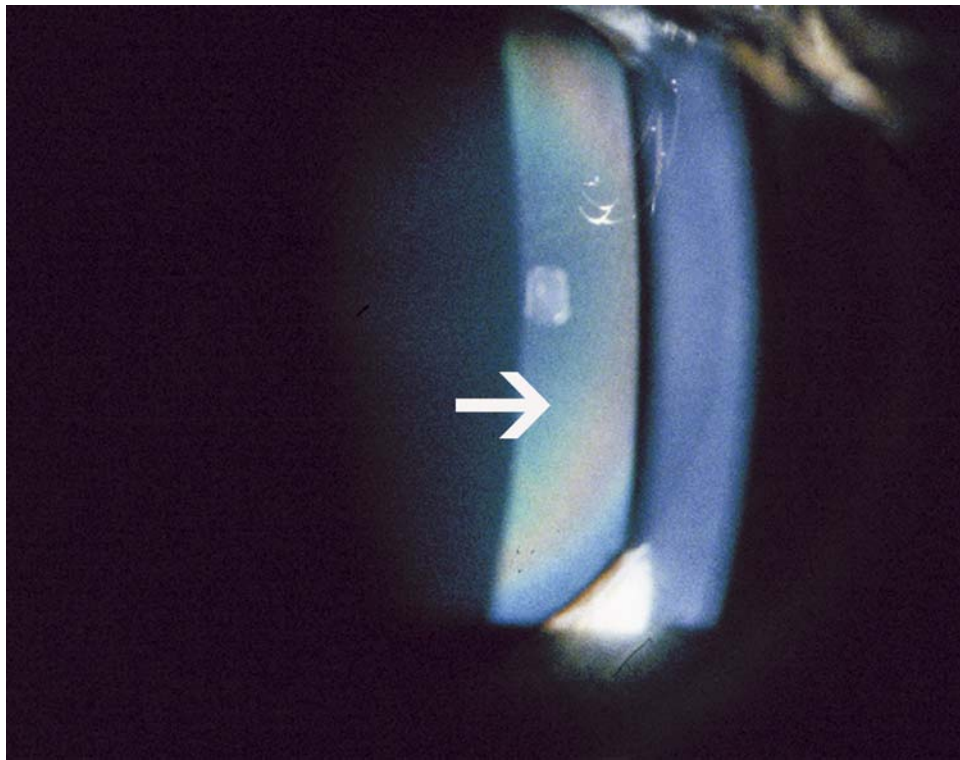


FIGURE 1

Slit-lamp photograph demonstrating polychromatic hue from peripheral aspect of anterior lens capsule (arrow). This band measures about 2 to 3 mm in width and is present around the circumference of the anterior lens capsule. There is a colorless area of capsule between the band and the lens equator.

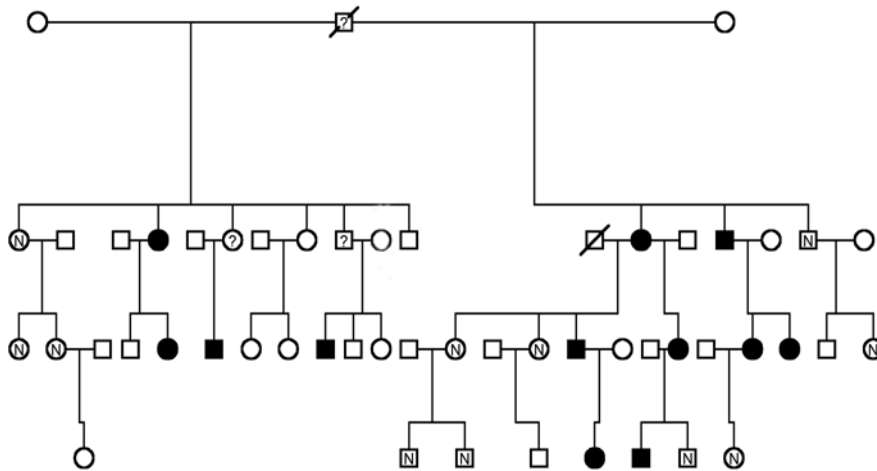


FIGURE 2A

Pedigrees of family 1. Squares = males; circles = females; filled symbols = affected; clear symbols with N = examined, unaffected; clear symbols = not examined; slashed symbol with ? = deceased, possibly affected; slashed symbol without ? = deceased.

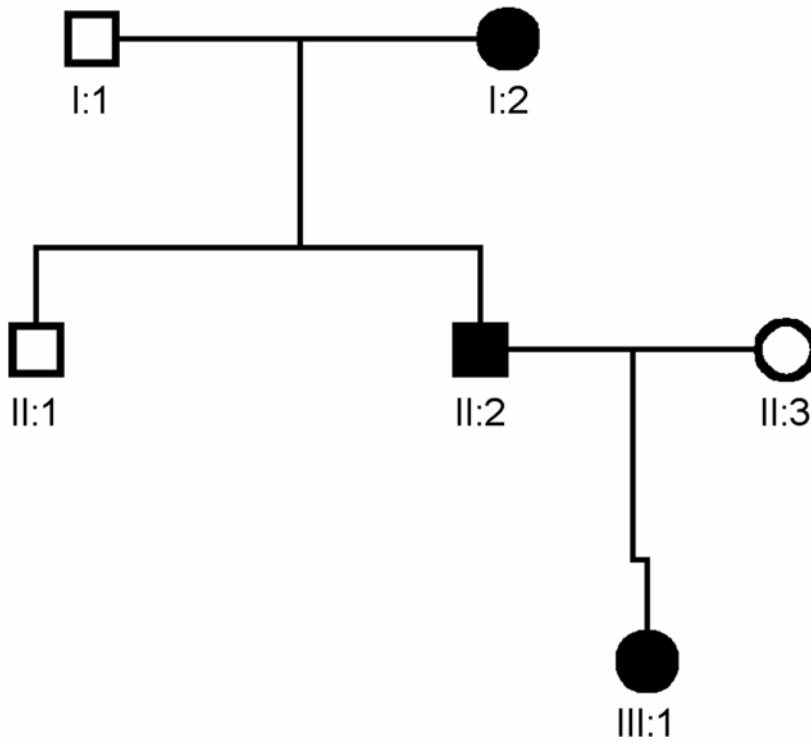


FIGURE 2B

Pedigrees of family 2. See Figure 2A for key.

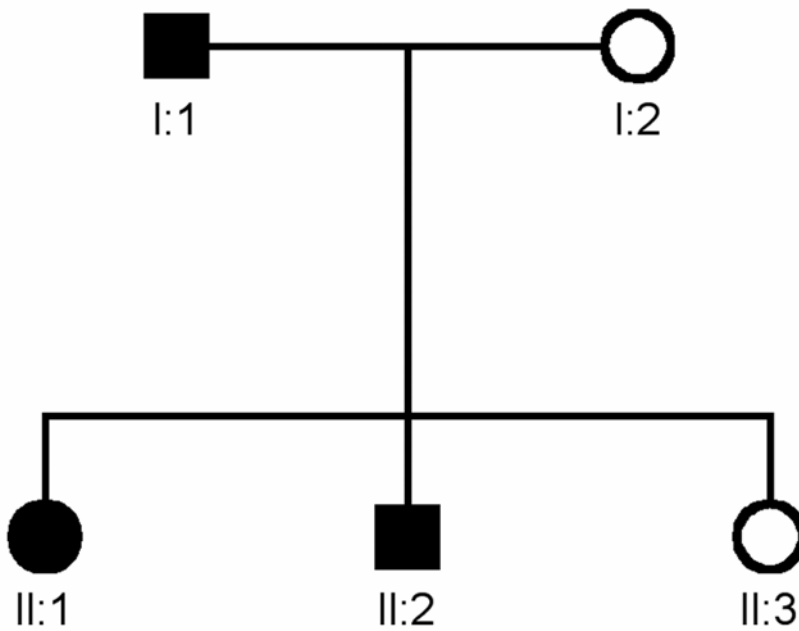


FIGURE 2C

Pedigrees of family 3. See Figure 2A for key.

TABLE. CLINICAL OCULAR DATA FOR MEMBERS OF FAMILIES 2 AND 3

FAMILY/PATIENT	AGE (YEARS)	VISION OD, VISION OS	POLYCHROMASIA CAPSULARE	OTHER FINDINGS
2/I:2 (grandmother)	65	20/30 20/40	Yes	Mild cataracts
2/I:1 (grandfather)	63	20/25 20/25	No	Macular drusen
2/II:2 (older son)	43	20/20 20/20	Yes	Mild cataracts
2/II:1 (younger son)	40	20/20 20/20	No	Radial keratotomy scars
2/III:1 (granddaughter)	19	20/20 20/20	Yes	None
3/I:1 (father)	33	20/20 20/20	Yes	Macular drusen
3/II:1 (older daughter)	10	20/20 20/20	Yes	Optic nerve drusen
3/II:2 (son)	6	20/20 20/20	Yes	Choroidal nevus
3/II:3 (younger daughter)	2	Fix and follow OU	No	None

DISCUSSION

We are unaware of any lesion or pathologic lens condition that has a similar appearance to the one we are describing in the present three families and that had been reported in only one previous communication.¹ Because of the location of the abnormal coloration in the lens capsule, we considered underlying systemic conditions such as Wilson's disease, ocular copper deposition associated with benign monoclonal gammopathy, and hypercupremia. These conditions were all ruled out in the proband and granddaughter in family 1. Furthermore, none of the affected individuals in all three families and in the two previously reported families had any clinical evidence of these conditions at any age. We also considered the exfoliation syndrome. However, none of the affected individuals had any flaking or exfoliation material, nor did they have elevated intraocular pressure or phakodonesis. The other ocular problems in some of the affected family members, such as uveitis and presumed ocular histoplasmosis in the proband, are probably coincidental because they were not observed in any other affected individuals.

We believe that polychromasia capsulare (multicolored capsule) is a benign autosomal dominant ocular trait. Male-to-male transmission and the occurrence in consecutive generations are supportive of this mode of inheritance. The condition is best described as a circular peripheral polychromatic band of anterior lens capsule discoloration with a predominantly green hue and an additional rainbow of colors on both edges. The discoloration is present in very early childhood and possibly from birth. It appears to be benign and nonprogressive, because we have not found the intensity or tint to vary between the youngest and the oldest affected individuals. This condition may be more common than previously thought, and additional observations will provide a better estimate of its prevalence. The dominant gene mutation causing this capsular discoloration could have led to the deposition of a polychromatic material in the lens capsule during lens development. The polychromatic region corresponds to the area of the capsule that is rich in fibrillin, as opposed to the central part, which is predominantly composed of collagen.² It is possible that a variant of fibrillin or of collagen has led to a region of the capsule with such physical properties that incident light is diffracted in this peculiar polychromatic fashion. There is also a remote possibility that this same variant of collagen has affected Bruch's membrane and has led to what has been diagnosed as presumed ocular histoplasmosis in the proband of family 1, or to the drusen and cataracts in other family members. The examination of capsular surgical specimens obtained at the time of cataract surgery in the older members of these families should provide additional clues to the nature and etiology of this unusual condition. Linkage analysis to collagen and fibrillin loci is under way in order to resolve possible underlying pathogenetic mechanisms.

REFERENCES

1. Knox D, Wolfe RL, Murdoch JL, et al. Hereditary tinted lenses in two families. In: *Birth Defects Original Article Series*. Vol V, No. 2. New York: Alan R. Liss; 1969:166.

2. Mir S, Wheatley HM, Maumenee Hussels IE, et al. A comparative study of the fibrillin microfibrillar system in the lens capsule of normal and Marfan syndrome patients. *Invest Ophthalmol Vis Sci* 1998;39:84-93.

PEER DISCUSSION

DR J. BRONWYN BATEMAN. It is a distinct pleasure to discuss this interesting report and provocative disorder. Before I comment on the condition, I would like to congratulate Dr Traboulsi and his colleagues for their observational skills.

In my lifetime, genetics has been transformed from observational studies to sequencing of DNA. It was only in 1956, that the number of human chromosomes was correctly identified as 22 pairs and two gender-determining chromosomes, X and Y – as this early chromosomal analysis shows. Prior to this date, it was thought there were 48 chromosomes.

It is this type of study that leads to the linkage analysis studies and the identification of the gene. What might this disease be? The authors were wise to consider Wilson disease, a disorder of copper metabolism. The sunflower cataract in a patient with Wilson disease, the color is not iridescent but a characteristic blue. From the location and configuration of the opacity in this patient with Wilson disease, we learn about aqueous fluid dynamics. Thus, although the color of the opacity in these patients of Drs Traboulsi, Chung and Koors brings copper to mind, the position of the iridescent band is not likely to be from the aqueous. Based on the position of 'breeness' in pseudoexfoliation, the position of the band is too peripheral to be in the region where the iris touches the anterior capsule.

To further complicate the speculation of the mechanism of this disease, the gene for Wilson disease is very similar to the gene for Menkes disease, an x-linked disorder association with a retinal degeneration but not copper deposition on the lens. The sequences are homologous. Thus, copper might still be a clue. Reviewing photographs of patients with Alport syndrome and a defect of Type IV collagen in the central portion of the lens supports the idea that perhaps a molecule in the peripheral lens capsule is altered, changing the color and refractive composition.

I am struck by the other ocular diseases in affected members. I wonder if the iritis and macular neovascularization in the 52-year-old proband is related. In the two other reported families, a 63-year-old and a 33-year-old have macular drusen. As additional 'food for thought', one child has optic nerve drusen. So, I would not relegate this autosomal dominant condition to the lens only.

I would suggest that Dr Traboulsi and his colleagues attempt to find the original families published by Dr David Knox and his colleagues in 1969. Perhaps a long-term evaluation might shed light on the full manifestations of the gene and one of the two could present next year.

DR EDWARD L. RAAB. Wilson disease usually involves patients that have significant systemic illness and not merely eye findings. This was a research study and therefore appropriate other studies were performed for Wilson disease. But do you feel it is necessary to evaluate for Wilson disease, at least in the older individuals? Would the fact that they were otherwise systemically normal negate the necessity to work them up?

DR M. EDWARD WILSON. Some of these patients are now of the age where perhaps pseudophakia is more common than phakia. Did any have cataract surgery? It appears that the rings may have been in the area where a capsulorrhexis would be performed and I wondered if this would affect the elasticity or the ease of tearing of the capsule. I would urge you to plan exactly what special studies you might want to perform on that capsule cap before some of these patients have cataract surgery. Perhaps their general ophthalmologists need to be made aware of the desire to obtain that specimen for further study.

DR GEORGE L. SPAETH. You described this condition as a trait, not a disease. This impressed me since it demonstrated a nicety concerning you about the distinction between a disease and a trait. Where did that interesting nicety and importance of concern come from?

DR ELIAS I. TRABOULSI. I do believe that this is a problem in the structure of the peripheral lens capsule. I agree with Dr Bateman that we should evaluate carefully the other parts of the eye, especially in view of the observations of macular degeneration. In further discussions with Dr John Koors about the posterior aspects in our main proband, he was kind of soft on the description of the drusen. A patient with Alport Syndrome, for example, will have problems with the anterior lens capsule and they would have these very small, drusen-like changes in the fundus that would not be unexpected in view of the fact that Bruchs membrane has a predominant collagen component. We will evaluate that more carefully.

Wilson disease would be extremely unusual, if not impossible so I agree with Dr Raab that a workup for this disease is not necessary. The reason that we obtained the workup in two family members was to confirm that this was perhaps not a more benign form of Wilson disease. I have a signed contract with the proband that she will come to the Cole Eye Institute for her cataract surgery and we will obtain that capsulorrhexis specimen and perform the appropriate studies.

Dr Spaeth, I am sensitive about the distinction between a disease and a trait. It stems from my training and practice as a geneticist. When you deal with families who may look a little bit different, for example, someone may be just tall and slender and have mitral valve prolapse and not have Marfan syndrome. Or someone may just have a facial hemangioma and not have Sturge-Weber syndrome. If you make the mistake of telling them that they have Sturge-Weber syndrome because they have a facial hemangioma, it carries a negative connotation and affects their lives in some way. The same is true with Marfan syndrome. If you tell them that you have a variant collagen or some connective tissue in your body that is giving you certain features such as tall and thin whereas the next person is short and stubby. We should all be aware and sensitive to what we call a disease and what we call a trait, similar to the correct terminology for someone who has ocular hypertension or glaucoma.