

HUMAN INTRAOCULAR PENETRATION PHARMACOKINETICS OF MOXIFLOXACIN 0.5% VIA TOPICAL AND COLLAGEN SHIELD ROUTES OF ADMINISTRATION

BY Seenu M. Hariprasad MD,* **William F. Mieler MD**, Gaurav K. Shah MD, Kevin J. Blinder MD, Rajendra S. Apte MD, Nancy M. Holekamp MD, Matthew A. Thomas MD, Jingduan Chi PhD, AND Randall A. Prince PharmD

ABSTRACT

Purpose: To determine penetration of moxifloxacin 0.5% into human aqueous and vitreous via topical and collagen shield routes of administration.

Methods: Moxifloxacin 0.5% was administered prior to vitrectomy surgery through one of three routes: topical drops every 2 hours for 3 days, versus topical drops every 6 hours for 3 days, versus delivery using a 24-hour dissolvable cross-linked corneal collagen shield. Aqueous and vitreous moxifloxacin concentrations were assayed using high-performance liquid chromatography

Results: Mean moxifloxacin concentrations in the every-2-hour group for aqueous (n = 9) and vitreous (n = 10) were 2.28 ± 1.23 $\mu\text{g/mL}$ and 0.11 ± 0.05 $\mu\text{g/mL}$, respectively. Mean moxifloxacin concentrations in the every-6-hour group for aqueous (n = 10) and vitreous (n = 9) were 0.88 ± 0.88 $\mu\text{g/mL}$ and 0.06 ± 0.06 $\mu\text{g/mL}$, respectively. Levels of minimum inhibitory concentration at which 90% of isolates are inhibited (MIC_{90}) were far exceeded in the aqueous for a wide spectrum of pathogens that most commonly cause postoperative endophthalmitis. Moxifloxacin concentration in the vitreous did not exceed the MIC_{90} for several key organisms. Delivery of moxifloxacin via a collagen shield revealed a mean aqueous concentration of 0.30 ± 0.17 $\mu\text{g/mL}$ 4 hours after placement (n = 5). Vitreous levels at 4 hours, as well as aqueous and vitreous levels at 24 hours, were negligible using this route of administration.

Conclusions: The findings of this investigation reveal that topically administered moxifloxacin 0.5% can achieve relatively high aqueous concentrations. Although aqueous moxifloxacin levels achieved through the use of a collagen shield delivery device are lower, there are several advantages to this route of delivery that make it appealing in the immediate postoperative period. Future studies will be needed to precisely define the role of fourth-generation fluoroquinolones and presoaked collagen shields in the prophylaxis or management of intraocular infections.

Trans Am Ophthalmol Soc 2004;102:149-157

INTRODUCTION

Bacterial endophthalmitis is one of the most serious complications after intraocular surgery. The microbiologic spectrum of infecting organisms in postoperative endophthalmitis was investigated in the Endophthalmitis Vitrectomy Study. This study represents the largest

number of postoperative endophthalmitis cases from which bacteriologic data were prospectively obtained. The vast majority (94.2%) of confirmed growth isolates were gram-positive pathogens, most commonly *Staphylococcus epidermidis* and *Staphylococcus aureus*. Gram-negative pathogens, the most common being *Proteus mirabilis*, accounted for only 5.9% of confirmed growth isolates.¹ The spectrum of infecting organisms in post-traumatic endophthalmitis differs from those of postoperative endophthalmitis, with *Bacillus* species playing a more prominent role.²

Numerous strategies have been described to try to decrease the incidence of postoperative endophthalmitis.³ Unfortunately, it is difficult to demonstrate superiority of one prophylactic strategy over another owing to the low occurrence rate of postoperative infection. The fluoroquinolones have been commonly used for prophylaxis during the perioperative period, typically through the

From Barnes Retina Institute, Department of Ophthalmology and Visual Science, Washington University School of Medicine, St Louis, Missouri (Drs Hariprasad, Shah, Blinder, Apte, Holekamp, and Thomas); Department of Ophthalmology and Visual Science, University of Chicago, Chicago, Illinois (Dr Mieler); and College of Pharmacy, University of Houston, Houston, Texas (Dr Chi and Dr Prince). Funding support received by the Retina Research and Development Foundation, St Louis, Missouri.

*Presenter.

Bold type indicates **AOA** member.

topical route of administration. The choice of antibiotic can be difficult because there are many different aspects by which the efficacy of an antibiotic is determined. One of these aspects is bioavailability. The bioavailability of an antibiotic determines its ability to penetrate into the tissues of concern and reach bacteria. In order to be bioavailable, a topical ophthalmic antibiotic must have a high rate of penetration and good solubility. The purpose of this investigation is to determine the penetration pharmacokinetics of moxifloxacin 0.5% ophthalmic solution into the human aqueous and vitreous via topical and collagen shield routes of administration.

Moxifloxacin 0.5% (Vigamox; Alcon Laboratories, Inc, Fort Worth, Texas) and gatifloxacin 0.3% (Zymar; Allergan, Inc, Irvine, California) are two newly released fourth-generation fluoroquinolones. They have a spectrum of activity encompassing gram-positive and gram-negative bacteria, including *S epidermidis*, *S aureus*, *S pneumoniae*, *S pyogenes*, *H influenzae*, *E coli*, *Bacillus cereus*, *N gonorrhoeae*, and *P mirabilis*. Additionally, the fourth-generation fluoroquinolones have good activity against atypical pathogens such as *Mycoplasma*, *Legionella*, and *Chlamydia* species, as well as the anaerobic organism *P acnes*.^{4,5} New-generation fluoroquinolones, such as moxifloxacin, gatifloxacin, grepafloxacin, and trovafloxacin, represent advances in the evolution of this antibiotic class. The more favorable pharmacokinetic properties of the previously mentioned agents are due to alterations of the original fluoroquinolone moiety. For example, moxifloxacin and gatifloxacin possess an 8-methoxy side-chain (Figure 1), which may be responsible for their enhanced activity against gram-positive organisms, atypical pathogens, and anaerobes while retaining potencies and broad-spectrum coverage against gram-negative organisms comparable to older-generation fluoroquinolones. Each of the fourth-generation fluoroquinolones has its own subtle strengths by in vitro testing;^{6,7} however, further studies will reveal if these in vitro differences are clinically relevant.

We chose to study the penetration pharmacokinetics

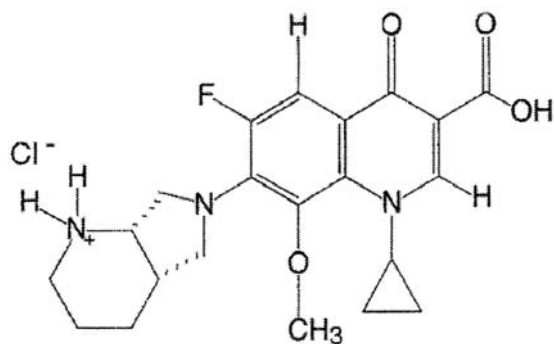


FIGURE 1

Chemical structure of moxifloxacin hydrochloride (C₂₁H₂₄FN₃O₄-HCl).

of topically applied moxifloxacin 0.5% ophthalmic solution into the human aqueous and vitreous for two reasons. First, older-generation fluoroquinolones, such as ofloxacin 0.3%, ciprofloxacin 0.3%, and levofloxacin 0.5%, have been shown to achieve effective levels in the aqueous, but not the vitreous, after topical administration in the noninflamed eye.⁸⁻¹⁰ Second, the MIC₉₀ values of moxifloxacin against the pathogens most commonly responsible for postoperative, post-traumatic, and bleb-associated endophthalmitis were generally lower than those of the other fluoroquinolone antibiotics we surveyed (Table 1).

The corneal collagen shield was originally developed as a bandage lens for the treatment of corneal epithelial damage. Prior investigations have demonstrated that the collagen shield may be well suited for drug delivery in the perioperative setting and has several advantages over topical and subconjunctival routes of antibiotic administration.¹¹⁻¹³ For these reasons, we chose to determine the intraocular penetration of moxifloxacin 0.5% using a 24-hour dissolvable cross-linked corneal collagen shield device.

METHODS

The study was carried out with the approval of the Washington University School of Medicine Institutional Review Board. Thirty adult patients, age range 55 to 86 years (68.2 ± 7.9 years), undergoing elective pars plana vitrectomy surgery between September 2003 and February 2004 at the Barnes Retina Institute were included in the study. Exclusion criteria included the following: known sensitivity to fluoroquinolones, renal disease (creatinine level >1.8 mg/dL), use of any other antibiotic(s) in the preceding 3 weeks, pregnancy or currently breast-feeding, current use of a class IA or III antiarrhythmic agent, previously vitrectomized eyes, fresh vitreous hemorrhage as indication for vitrectomy (less than 1 month old), or active endophthalmitis.

After informed consent was obtained, the first 20 patients were asked to self-administer topical moxifloxacin 0.5% ophthalmic solution for 3 days prior to surgery in the eye scheduled for operation. The first 10 patients received one drop of moxifloxacin every 2 hours (Q2H), and the second 10 patients received one drop of moxifloxacin every 6 hours (Q6H). On the day of surgery, the patients continued dosing as they had on the 3 preceding days. Additionally, topical 0.5% moxifloxacin was administered to all eyes 5 to 10 minutes preoperatively as a single drop. Patients were asked to return their bottle of moxifloxacin on the day of surgery to determine compliance to their assigned dosing regimen.

The last 10 patients enrolled received a 24-hour dissolvable cross-linked corneal collagen shield (Oasis Medical, Glendora, California) presoaked in moxifloxacin

TABLE I. IN VITRO SUSCEPTIBILITIES OF TOPICALLY ADMINISTERED MOXIFLOXACIN, LEVOFLOXACIN, OFLOXACIN, AND CIPROFLOXACIN

	MIC ₉₀ VALUES (µg/mL) ^a			
	MOXIFLOXACIN 0.5% Q2H / Q6H	LEVOFLOXACIN 0.5% ^{8,†}	OFLOXACIN 0.3% ^{9,†}	CIPROFLOXACIN 0.3% ^{10,†}
Mean aqueous penetration	2.28 ± 1.23 / 0.88 ± 0.88	1.00 ± 0.48	1.44 ± 0.24	0.44 ± 0.07
Mean vitreous penetration	0.11 ± 0.05 / 0.06 ± 0.06	–	0.37 ± 0.05	0.22 ± 0.04
Gram-positive organisms				
<i>Staphylococcus epidermidis</i>	0.13	0.50	0.50	1.00
<i>Staphylococcus aureus</i> (MSSA)	0.06	0.25	0.50	0.50
<i>Streptococcus pneumoniae</i>	0.25	2.00	2.00	2.00
<i>Streptococcus pyogenes</i>	0.25	1.00	2.00	1.00
<i>Bacillus cereus</i>	0.13‡	–	0.50	–
<i>Enterococcus faecalis</i>	1.00	2.00	4.00	4.00
Gram-negative organisms				
<i>Proteus mirabilis</i>	0.25	0.25	0.125	0.06
<i>Pseudomonas aeruginosa</i>	32.0	32.0	4.00	8.00
<i>Haemophilus influenzae</i>	0.06	0.06	4.00	0.016
<i>Escherichia coli</i>	0.008	0.03	0.125	0.016
<i>Klebsiella pneumoniae</i>	0.13	0.13	0.50	0.06
<i>Neisseria gonorrhoeae</i>	0.016	0.016	–	0.008
Anaerobic organisms				
<i>Bacteroides fragilis</i>	2.00	2.00	–	8.00
<i>Propionibacterium acnes</i>	0.25‡	–	–	–

MIC₉₀, minimum inhibitory concentration at which 90% of isolates are inhibited; MSSA, methicillin-sensitive *S aureus*.

^aMIC₉₀ data are from Bauernfeind⁴ and Osato et al.⁵

†Dash indicates data not available.

‡On file, Alcon Laboratories, Inc.

0.5% for 10 minutes prior to insertion into the eye scheduled for surgery. After placement, the eye was patched with a soft shield. The collagen shield was placed in the eye for approximately 4 hours (4H) in the first five patients and 24 hours (24H) in the second five patients prior to surgery.

Aqueous and vitreous samples were obtained before infusion of any intraocular irrigating solution in order to obtain pure samples. In the operative suite, approximately 0.1 mL of aqueous fluid was aspirated through a paracentesis site using a 30-gauge needle attached to a syringe. Within 10 minutes, 0.2 to 0.3 mL of vitreous fluid was obtained using a vitreous cutting device attached to a syringe via a short length of tubing. Aqueous and vitreous samples were immediately frozen at –83°C. These samples were shipped with dry ice in appropriate packaging material to the University of Houston College of Pharmacy, Houston, Texas. Moxifloxacin concentrations were determined in each of the samples using a previously described high-performance liquid chromatography technique.¹⁴ Aqueous and vitreous moxifloxacin concentrations were compared with already established in vitro MIC₉₀ data.^{4,5} Student's *t* test was performed to determine if any significant differences existed between various

subsets of patients.

RESULTS

Indications for operation in the 30 patients were as follows (Tables 2 and 3): macular hole (10 patients), epiretinal membrane (10), branch retinal vein occlusion (3), central retinal vein occlusion (2), diabetic macular edema (2), chronic cystoid macular edema (1), vitreomacular traction syndrome (1), and intraocular lens exchange (1).

Mean moxifloxacin concentrations in the topical Q2H group for aqueous (n = 9) and vitreous (n = 10) were 2.28 ± 1.23 µg/mL and 0.11 ± 0.05 µg/mL, respectively. Mean moxifloxacin concentrations in the topical Q6H group for aqueous (n = 10) and vitreous (n = 9) were 0.88 ± 0.88 µg/mL and 0.06 ± 0.06 µg/mL, respectively. Although the mean aqueous concentration of moxifloxacin was significantly different between the Q2H and the Q6H groups, this was not the case for the vitreous (*P* = .01 and *P* = .08, respectively) (Table 2 and Figure 2).

Compliance to assigned topical dosing regimens was determined by counting the number of drops remaining in each patient's moxifloxacin 0.5% bottle on the day of surgery. To determine the number of drops administered,

TABLE 2. PATIENT CHARACTERISTICS AND INTRAOCULAR MOXIFLOXACIN CONCENTRATIONS AFTER TOPICAL ADMINISTRATION

PATIENT NO.	AGE (YR)	INDICATION FOR SURGERY	PHAKIC STATUS	DOSING REGIMEN	NO. OF DROPS ADMINISTERED	AQUEOUS $\mu\text{g/mL}$	VITREOUS $\mu\text{g/mL}$
1	67	MH	Phakic	Q2H	39	–°	0.07
2	58	CME	Pseudo	Q2H	49	0.173	0.10
3	69	MH	Phakic	Q2H	47	2.393	0.07
4	70	ERM	Phakic	Q2H	47	4.244	0.10
5	55	MH	Phakic	Q2H	38	2.316	0.07
6	68	ERM	Pseudo	Q2H	25	3.182	0.18
7	69	MH	Pseudo	Q2H	44	1.713	0.08
8	84	MH	Pseudo	Q2H	63	3.488	0.13
9	66	CRVO	Pseudo	Q2H	38	1.394	0.09
10	77	BRVO	Pseudo	Q2H	39	1.655	0.22
11	76	ERM	Pseudo	Q6H	17	0.301	0.08
12	55	IOL Exchange	Pseudo	Q6H	27	0.122	0.20
13	72	MH	Pseudo	Q6H	26	0.955	0.08
14	61	BRVO	Phakic	Q6H	21	2.198	0.03
15	66	ERM	Phakic	Q6H	27	0.769	0.02
16	86	ERM	Pseudo	Q6H	13	0.294	0.06
17	69	ERM	Pseudo	Q6H	–†	0.296	0.03
18	61	MH	Phakic	Q6H	20	0.816	0.03
19	70	ERM	Phakic	Q6H	21	2.709	0.04
20	59	MH	Phakic	Q6H	23	0.35	–°

BRVO, branch retinal vein occlusion; CME, chronic cystoid macular edema; CRVO, central retinal vein occlusion; ERM, epiretinal membrane; IOL, intraocular lens; MH, macular hole.

°Not detected by high-performance liquid chromatography, presumably due to low concentration or insufficient sample volume.

†Moxifloxacin 0.5% bottle not returned.

this number was subtracted from 78, because this is the number of drops in an average 3-mL moxifloxacin 0.5% bottle (on file, Alcon Laboratories, Inc). Only one patient (No. 17, Table 2) did not return a bottle. The mean number of moxifloxacin drops administered in the Q2H and the Q6H groups was 42.90 ± 9.86 and 21.67 ± 4.72 drops, respectively.

Aqueous topical data from patient 1 and vitreous topical data from patient 20 were removed from the study because either there was insufficient sample volume to perform high-performance liquid chromatography

(HPLC) or concentrations were too low to be detected by HPLC. In both the Q2H and the Q6H groups, there appeared to be several values that were considered outliers. For example, patient 2 had aqueous levels approximately 13 times below the mean of the rest of the Q2H group. We chose to include all data obtained in the study, because the investigators could not explain these high or low concentrations and attributed them to variability of moxifloxacin pharmacokinetics in individual patients (Table 2).

Four of the 10 patients in the Q2H group and five of the 10 patients in the Q6H group were phakic. In the Q2H group, aqueous and vitreous moxifloxacin concentrations were not significantly different when comparing phakic versus pseudophakic eyes ($P = .25$ and $P = .10$, respectively). The same was found in the Q6H group, where aqueous and vitreous moxifloxacin concentrations were not significantly different when comparing phakic versus pseudophakic eyes ($P = .08$ and $P = .12$, respectively).

Collagen shields were placed for 3.75 ± 1.41 hours prior to surgery in the 4H group and 24.80 ± 0.84 hours in the 24H group. Mean moxifloxacin aqueous concentrations in the 4H group ($n = 5$) were $0.30 \pm 0.17 \mu\text{g/mL}$. Two of five patients in the 4H group had detectable vitreous moxifloxacin levels of $0.03 \mu\text{g/mL}$. In the 24H collagen shield group, two of five patients had detectable aqueous

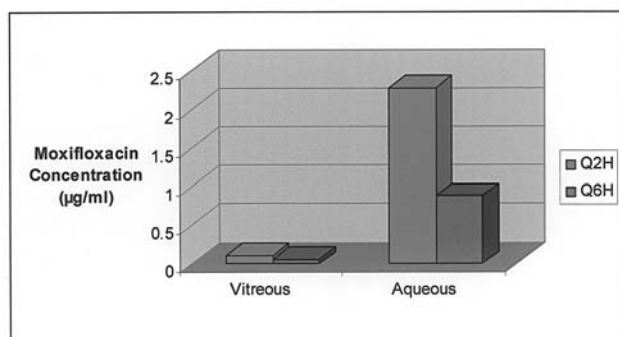


FIGURE 2

Mean intraocular moxifloxacin concentrations achieved after topical administration.

ous moxifloxacin levels of $0.04 \pm 0.01 \mu\text{g/mL}$. Vitreous levels of moxifloxacin were undetectable in all five patients in the 24H group (HPLC assay for moxifloxacin can detect levels $>0.025 \mu\text{g/mL}$) (Table 3).

No serious adverse reactions were attributed to the antibiotic agent or the collagen shield. In our series, only one patient from the Q2H topical group complained of mild ocular discomfort. No patients in our series complained of nonocular adverse events. Corneal clarity in all patients included in this study was described as excellent by the contributing surgeons.

DISCUSSION

After cataract extraction, bacterial endophthalmitis is most commonly caused by *S epidermidis* (70% of isolates in the Endophthalmitis Vitrectomy Study).¹ This typically presents as a moderately severe infection 5 to 7 days after surgery. Less commonly, two other forms of endophthalmitis can take place after cataract extraction. The first is a chronic, indolent endophthalmitis that presents several months after surgery and is usually caused by *P acnes*.¹⁵ A second, less common form of postoperative endophthalmitis is an early, fulminant type usually presenting 2 to 4 days after surgery, which is caused by *Streptococcus* or *Staphylococcus* species as well as gram-negative organisms (most commonly *P mirabilis*).¹ One reason we chose to study the intraocular penetration of moxifloxacin is that the MIC_{90} values of moxifloxacin against the pathogens most commonly responsible for postoperative, post-traumatic, and bleb-associated endophthalmitis were generally lower than those of the other fluoroquinolone antibiotics we surveyed (Table 1). In our study, MIC_{90} levels were far exceeded in the aqueous for a wide spectrum of pathogens in both the topical

Q2H and Q6H groups, including *S epidermidis*, *S aureus*, *S pneumoniae*, *S pyogenes*, *P acnes*, *H influenzae*, *E coli*, *B cereus*, *N gonorrhoeae*, *P mirabilis*, and other organisms. Concentration of moxifloxacin in the vitreous after topical administration did not exceed the MIC_{90} for several organisms; however, in the Q2H group, the MIC at which 50% of isolates are inhibited (MIC_{50}) was exceeded for *S epidermidis*, *S aureus*, *S pneumoniae*, *H influenzae*, *B cereus*, and other gram-negative organisms.⁶ Topically administered moxifloxacin was unable to achieve intraocular levels effective against *Pseudomonas*; furthermore, the MIC_{90} for *Enterococcus* was only exceeded in the Q2H aqueous group. Although *Pseudomonas* and *Enterococcus* are only very rarely encountered in postoperative endophthalmitis,¹ moxifloxacin 0.5% may not be a suitable treatment choice for intraocular infections known to be caused by these organisms.

Another reason we chose to study the intraocular penetration of topically administered moxifloxacin 0.5% is that older-generation fluoroquinolones, such as levofloxacin 0.5%, ofloxacin 0.3%, and ciprofloxacin 0.3%, have been shown to achieve effective levels in the aqueous, but not the vitreous, after topical administration in the noninflamed human eye.⁸⁻¹⁰ Table 1 compares the mean intraocular concentrations achieved with several other fluoroquinolones agents, as well as their corresponding MIC_{90} values, against the pathogens most commonly responsible for bacterial endophthalmitis. The intent of this table is not to directly compare the intraocular penetration of the different agents, since the dosing frequency of each investigated fluoroquinolone was different. Additionally, given the study design of these types of investigations, it is difficult to precisely determine if samples are being obtained during drug peak or trough levels. Given these limitations of Table 1, several important findings are apparent. First,

TABLE 3. PATIENT CHARACTERISTICS AND INTRAOCULAR MOXIFLOXACIN CONCENTRATIONS AFTER COLLAGEN SHIELD PLACEMENT

PATIENT NO.	AGE (YR)	INDICATION FOR SURGERY	PHAKIC STATUS	GROUP	AQUEOUS $\mu\text{g/mL}$	VITREOUS $\mu\text{g/mL}$
1	75	DME	Pseudo	4H	0.077	–
2	70	MH	Phakic	4H	0.22	–
3	76	ERM	Phakic	4H	0.328	0.03
4	75	ERM	Phakic	4H	0.555	–
5	59	CRVO	Phakic	4H	0.33	0.03
6	76	BRVO	Pseudo	24H	–	–
7	68	MH	Phakic	24H	0.046	–
8	62	DME	Pseudo	24H	–	–
9	66	ERM	Phakic	24H	–	–
10	60	VMTx	Pseudo	24H	0.025	–

BRVO, branch retinal vein occlusion; CRVO, central retinal vein occlusion; DME, diabetic macular edema; ERM, epiretinal membrane; MH, macular hole; VMTx, vitreomacular traction syndrome.

*Dash indicates not detected by high-performance liquid chromatography, presumably due to low concentration or insufficient sample volume.

no topically administered fluoroquinolone investigated achieves intravitreal levels sufficient to exceed the MIC₉₀ for the organisms that most commonly cause bacterial endophthalmitis. Intravitreal concentration of moxifloxacin 0.5% Q2H comes very close to the MIC₉₀ for *S epidermidis* (the most common causative organism in bacterial endophthalmitis). This concentration may be sufficient for prophylaxis, but is not sufficient for treatment of active infection. Previous studies suggest that intraocular penetration of systemic antibiotics may be higher in an eye that has sustained trauma, is infected, or is inflamed (ie, the postoperative eye).^{16,17} This may be due to disruption of the blood-ocular barrier, and it is conceivable that the intravitreal penetration of topically administered moxifloxacin may be high enough to exceed the MIC₉₀ level for *S epidermidis* and several other organisms of concern in the postoperative setting. Another finding that becomes apparent upon reviewing Table 1 is that compared to older-generation fluoroquinolones, moxifloxacin concentration achieved in the aqueous has fewer gaps in coverage for the organisms most commonly implicated in bacterial endophthalmitis.

Previous studies have demonstrated that orally administered fourth-generation fluoroquinolones can achieve therapeutic levels in the noninflamed human eye. Garcia-Saenz and associates¹⁸ investigated the penetration of orally administered moxifloxacin into the human aqueous humor for potential use as a prophylactic agent in cataract surgery. They found that moxifloxacin achieved a mean aqueous concentration of 2.33 ± 0.85 µg/mL. Unfortunately, penetration of moxifloxacin into the vitreous was not investigated in this study. Gatifloxacin, another fourth-generation fluoroquinolone, has been shown to achieve levels as high as 1.34 ± 0.34 µg/mL and 1.08 ± 0.54 µg/mL in the human vitreous and aqueous after oral administration, respectively.¹⁹ Although oral administration of a fourth-generation fluoroquinolone results in intravitreal concentrations several times higher than after topical administration, an interesting finding is that topically administered Q2H moxifloxacin 0.5% can achieve aqueous levels comparable to those after oral administration. Therefore, topically administered moxifloxacin 0.5% may be useful in the management of infections limited to the anterior segment. One example of such an infection is localized conjunctival filtering bleb infection, or "blebitis." The most common causative organisms in delayed-onset bleb-associated endophthalmitis are *Streptococcus* and *Staphylococcus* species.²⁰ *H influenzae* is also commonly encountered in this condition. The concentration of moxifloxacin achieved after topical administration in the aqueous is several times higher than the MIC₉₀ for these organisms. If blebitis progresses to bleb-associated endophthalmitis, one may consider the addition of an orally administered fourth-generation fluoroquinolone as an adjunct to the current

management of bleb-associated endophthalmitis.

The collagen shield data obtained from this study reveal that peak aqueous levels of moxifloxacin occur soon after surgery. This is when a high level of antibiotic is most needed to clear the anterior chamber of bacteria remaining in the eye. In the 4H collagen shield group, the MIC₉₀ and MIC₅₀ for several organisms that most commonly cause postoperative endophthalmitis were exceeded.^{4,6} By 24 hours, negligible levels of moxifloxacin were found in the eye. This is consistent with other studies investigating drug delivery from collagen shields, which show that peak intraocular drug levels occur in the first 4 hours of collagen shield application.²¹ Therapeutic moxifloxacin levels in the vitreous cannot be achieved with this method of drug delivery, and the clinical significance of this is yet to be determined.

There are several advantages to using collagen shields for moxifloxacin delivery in the immediate postoperative period. One such advantage is the ability to leave the eye patch undisturbed after surgery while the collagen shield releases antibiotic. Additionally, there is evidence that collagen shields have a beneficial effect on the corneal epithelium and promote healing.¹³ Collagen shields have advantages over subconjunctival injections as well; these include avoiding inadvertent globe perforation and subconjunctival hemorrhage. Additionally, pain associated with subconjunctival antibiotic injection can be avoided with the use of a collagen shield when cataract surgery is performed using topical anesthesia. Lastly, with the advent of sutureless 25-gauge vitrectomy surgery, the vitreoretinal specialist should consider the theoretical risk of serious retinal toxicity if a subconjunctivally administered antibiotic such as gentamicin were to enter an air-filled eye through an unsutured sclerotomy site.

Moxifloxacin 0.5% is unique in that it is free of preservatives, specifically benzalkonium chloride. The lack of this preservative is valuable when using a collagen shield delivery device, because there is a theoretical risk of preservatives causing corneal damage after sustained drug delivery. Corneal clarity was rated as excellent by the contributing surgeons for all 30 patients participating in this study; however, no formal fluorescein staining was performed to evaluate subtle corneal epithelial changes.

Moxifloxacin 0.5% is very well tolerated; the majority of adverse reactions are described as mild. These most commonly include dry eye, ocular hyperemia, ocular discomfort, and ocular itching. In our series, only one patient from the Q2H topical group complained of mild ocular discomfort. No patients in our series complained of nonocular adverse events. The dosage of moxifloxacin 0.5% recommended by Alcon Laboratories, Inc, is one drop three times a day (bacterial conjunctivitis indication). In our study design, we chose to use a regimen of Q2H and Q6H. Our rationale for dosing at Q2H was to

determine if intensive topical therapy could be used to obtain therapeutic levels in the vitreous. The Q6H dosing schedule was included in the study because this is a commonly used dosing regimen for cataract surgery prophylaxis. After calculation of the number of drops that were self-administered, patient compliance in both groups was considered excellent (Table 2).

The authors would like to emphasize that the purpose of this research is to provide proof-of-principle that moxifloxacin 0.5% can attain therapeutic intraocular concentrations. Moxifloxacin 0.5% may be beneficial for prophylaxis against the risk of infection after eye surgery or intravitreal injections; however, it should be noted that antibiotics are only one component of a thorough prophylactic regimen.

In summary, moxifloxacin has a spectrum of coverage that appropriately encompasses the most common causative organisms in endophthalmitis. The pharmacokinetic findings of this investigation reveal that topically administered moxifloxacin 0.5% can achieve relatively high aqueous concentrations. Although aqueous moxifloxacin levels achieved through the use of a collagen shield delivery device are lower, it is conceivable that intraocular levels of moxifloxacin may be higher in an eye that has undergone surgery. Additionally, there are several advantages to the collagen shield route of delivery that make it appealing in the immediate postoperative period. Future studies will be needed to precisely define the role of fourth-generation fluoroquinolones and presoaked collagen shields in the prophylaxis or management of intraocular infections.

REFERENCES

1. Han DP, Wisniewski SR, Wilson LA, et al. Spectrum and susceptibilities of microbiologic isolates in the Endophthalmitis Vitrectomy Study. *Am J Ophthalmol* 1996;122:1-17.
2. Affeldt JC, Flynn HW Jr, Forster RK, et al. Microbial endophthalmitis resulting from ocular trauma. *Ophthalmology* 1987;94:407-413.
3. Ciulla TA, Starr MB, Masket S. Bacterial endophthalmitis prophylaxis for cataract surgery: an evidence-based update. *Ophthalmology* 2002;109:13-24.
4. Bauernfeind A. Comparison of the antibacterial activities of the quinolones Bay 12-8039, gatifloxacin (AM 1155), trovafloxacin, clinafloxacin, levofloxacin, and ciprofloxacin. *J Antimicrob Chemother* 1997;40:639-651.
5. Osato MS, Jenson HG, Trousdale MD, et al. The comparative in vitro activity of ofloxacin and selected ophthalmic antimicrobial agents against ocular bacterial isolates. *Am J Ophthalmol* 1989;108:380-386.
6. Mather R, Karanchak LM, Romanowski EG, et al. Fourth generation fluoroquinolones: new weapons in the arsenal of ophthalmic antibiotics. *Am J Ophthalmol* 2002;133:463-466.
7. Kowalski RP, Dhaliwal DK, Karenchak LM, et al. Gatifloxacin and moxifloxacin: an in vitro susceptibility comparison to levofloxacin, ciprofloxacin, and ofloxacin using bacterial keratitis isolates. *Am J Ophthalmol* 2003;136:500-505.
8. Yamada M, Mochizuki H, Yamada K, et al. Aqueous humor levels of topically applied levofloxacin in human eyes. *Curr Eye Res* 2002;24:403-406.
9. Cekic O, Batman C, Yasar U, et al. Penetration of ofloxacin in human aqueous and vitreous humors following oral and topical administration. *Retina* 1998;18:521-525.
10. Cekic O, Batman C, Yasar U, et al. Human aqueous and vitreous humor levels of ciprofloxacin following oral and topical administration. *Eye* 1999;13:555-558.
11. Taravella MJ, Balentine J, Young DA, et al. Collagen shield delivery of ofloxacin to the human eye. *J Cataract Refract Surg* 1999;25:562-565.
12. Willoughby CE, Batterbury M, Kaye SB. Collagen corneal shields. *Surv Ophthalmol* 2002;47:174-182.
13. Simsek NA, Ay GM, Tugal-Tutkun I, et al. An experimental study on the effect of collagen shields and therapeutic contact lenses on corneal wound healing. *Cornea* 1996;15:612-616.
14. Stass H, Dalhoff A. Determination of BAY 12-8039, a new 8-methoxyquinolone, in human body fluids by high-performance liquid chromatography with fluorescence detection using on-column focusing. *J Chromatogr B Biomed Sci Appl* 1997;702:163-174.
15. Clark WL, Kaiser PK, Flynn HW Jr, et al. Treatment strategies and visual acuity outcomes in chronic postoperative *Propionibacterium acnes* endophthalmitis. *Ophthalmology* 1999;106:1665-1670.
16. Martin DF, Ficker LA, Aguilar HA, et al. Vitreous cefazolin levels after intravenous injection: effects of inflammation, repeated antibiotic doses, and surgery. *Arch Ophthalmol* 1990;108:411-414.
17. Alfaro DV, Hudson SJ, Rafanan MM, et al. The effect of trauma on the ocular penetration of intravenous ciprofloxacin. *Am J Ophthalmol* 1996;122:678-683.
18. Garcia-Saenz MC, Arias-Puente A, Fresnadillo-Martinez MJ, et al. Human aqueous humor levels of oral ciprofloxacin, levofloxacin, and moxifloxacin. *J Cataract Refract Surg* 2001;27:1969-1974.
19. Hariprasad SM, Mieler WF, Holz ER. Vitreous and aqueous penetration of orally administered gatifloxacin in humans. *Arch Ophthalmol* 2003;121:345-350.
20. Song A, Scott IU, Flynn HW Jr, et al. Delayed-onset bleb-associated endophthalmitis: clinical features and visual acuity outcomes. *Ophthalmology* 2002;109:985-991.
21. Kuwano M, Horibe Y, Kawashima Y. Effect of collagen cross-linking in collagen corneal shields on ocular drug delivery. *J Ocul Pharmacol Ther* 1997;13:31-40.

DISCUSSION

DR M. GILBERT GRAND. Endophthalmitis is among the most feared complications of intraocular surgery. While the incidence is low, because of the potential for cata-

strophic loss of vision, a variety of prophylactic methods have been embraced in hopes of preventing such infections. These include the use of antiseptic solutions to cleanse the operative field, proper sterilization of instruments, fluids, sutures and implants, and the prophylactic use of antibiotics. There is ample evidence that the use of preoperative povidone-iodine and antibiotics is associated with the reduction of viable microorganisms in the ocular flora, a reduction in the incidence of positive aqueous cultures at the completion of surgery, and a decreased incidence of endophthalmitis.¹ Considerable debate remains regarding the ideal prophylactic regimen; specifically, which antibiotic to use, the frequency and duration of treatment, route of administration, and the timing of administration of the drug in relation to surgery. There is also debate regarding potential deleterious effects of prophylactic use of antibiotics, including the potential acceleration of development of resistance, ocular toxicity, and alterations of the normal ocular flora to allow the growth of more virulent organisms.

The authors have presented data showing the bioavailability of topically applied moxifloxacin in the aqueous of non-inflamed eyes. Their data indicate concentrations of moxifloxacin in the aqueous that exceed the MIC₉₀ of organisms that most commonly cause acute postoperative bacterial endophthalmitis, blebitis, and filter bleb-associated endophthalmitis.

In reviewing this manuscript, it is apparent that the study population was, in fact, small and was further divided into multiple smaller treatment groups. The data points collected show a wide range of values, sometimes as wide as the mean value itself. Furthermore, compliance, as measured by drop count, appeared to be inconsistent. Yet despite these concerns, the study strongly suggests that topically applied moxifloxacin potentially may be of great value as a prophylactic antibiotic to reduce the risk of acute postoperative bacterial endophthalmitis. The authors, however, prudently remind us that the use of antibiotics, whether preoperatively, intraoperatively or postoperatively, is only one aspect in an overall scheme to prevent endophthalmitis. Perhaps the most significant finding of the study is the potential value of topical moxifloxacin in the treatment of *H. influenzae* or *Streptococcus*-induced blebitis and as an adjunct to intravitreal or systemic therapy in the treatment of filter bleb-associated endophthalmitis.

The data presented stimulate a number of questions: what is the ideal timing and frequency of administration of moxifloxacin preoperatively to achieve a significant reduction in viable microorganisms in the ocular flora? Will topical moxifloxacin administered for two hours prior to surgery achieve the same reduction in ocular flora and the same concentration in the aqueous as treatment

administered over three days preoperatively? Can modifications in the design and construction of the matrix of collagen shields be achieved that would allow a more prolonged administration of moxifloxacin or similar drugs to achieve adequate antibiotic concentrations in the aqueous and vitreous postoperatively without associated ocular toxicity? Finally, despite the potential broad spectrum coverage and bioavailability of moxifloxacin, in the hopes of preventing the induction of resistance, would it be prudent to avoid the use of fourth generation fluoroquinolones as prophylactic agents and reserve them only for treatment of infections such as blebitis or filter bleb endophthalmitis?

REFERENCE

1. Starr MB, Lally JM. Antimicrobial prophylaxis for ophthalmic surgery. *Surv Ophthalmol* 1995;39:485-501.

DR SEENU M. HARIPRASAD. Dr Grand's first question is astute. He asks if there is a difference in the ocular flora if moxifloxacin is dosed for three days versus for only two hours preoperatively? A very similar question was answered by Dr Ta and colleagues two years ago at Stanford; they dosed ofloxacin for three days in one group of patients and dosed ofloxacin in a second group one hour preoperatively. They found that positive conjunctival cultures were found prior to surgery in about 20 percent of eyes which received three days of ofloxacin versus 40 percent of eyes that received ofloxacin only right before surgery. Similarly, postoperatively, those eyes which had received ofloxacin for three days had less than 50 percent ocular surface contamination compared to the group that received ofloxacin only right before surgery (it should be noted that all patients received a povidone-iodine scrub). Therefore, this data strongly suggests that a longer preoperative antibiotic dosing regimen is more effective in eliminating bacteria from the ocular surface.

To address Dr Grand's second question, the effectiveness of a corneal collagen shield as a drug delivery device depends on its drug uptake and its subsequent rate of release. The factors that determine this include collagen shield cross-linking versus non-cross linking, dissolution time of the collagen shield, and water-solubility of the drug. A cross-linked shield (such as the one we used in this study) can provide more desirable drug delivery than non-cross linked shields because drug levels can be sustained for longer periods of time. Likewise, longer dissolution times are also preferable, and that is why we used a 24-hour collagen shield rather than a 12-hour shield. So to answer your question, Dr Grand, the design of a "better" collagen shield may be achieved by altering the molecular structure of the shield and possibly the

physicochemical properties of the drug.

Finally, the proper use of ophthalmic topical fluoroquinolones represents an insignificant selection pressure for promoting resistant bacteria. I use the term “proper” to mean the use of a topical antibiotic at therapeutic levels for a short period of time. Approximately 200,000 kilograms of fluoroquinolones are used annually of which only 24 kilograms constitute ocular use. Therefore, my impression is that agriculture, veterinary, general medicine, and surgical uses of fluoroquinolones have a much greater selection pressure for the development of resistant organisms compared to ophthalmology.

I would like to convey my gratitude to the program committee for allowing me to present our research today and once again I would like to thank Dr Grand for his meticulous review of our paper.

