

# SAFETY OF INTRAVITREAL VORICONAZOLE: ELECTRORETINOGRAPHIC AND HISTOPATHOLOGIC STUDIES

---

BY Hua Gao MD PhD, Mark Pennesi PhD, Kekul Shah MD, Xiaoxi Qiao MD PhD, Seenu M. Hariprasad MD, William F. Mieler MD,\* Samuel M. Wu PhD, AND Eric R. Holz MD

## ABSTRACT

**Purpose:** Voriconazole, a novel triazole antifungal agent, presents potent activity against a broad spectrum of yeast and molds. To determine whether it could be safely used as an intravitreal agent in the treatment of fungal endophthalmitis, retinal toxicity of voriconazole was examined in a rodent animal model.

**Methods:** Voriconazole solutions were serially diluted and injected intravitreally into eyes of normal adult Sprague-Dawley rats so that the final intravitreal concentrations were 5  $\mu\text{g}$ , 10  $\mu\text{g}$ , 25  $\mu\text{g}$ , 50  $\mu\text{g}$ , and 500  $\mu\text{g}/\text{mL}$  ( $N = 3$  for each concentration group). Saline was injected into the fellow eyes of each animal as controls. Three weeks after injections, electroretinograms (ERGs) were measured, and eyes were subsequently enucleated for histologic examination.

**Results:** In ERG studies, maximum scotopic b-wave,  $b_{\text{max}}$ , intensity needed for half saturation,  $I_{0.5}$ , and saturated a-wave amplitude were measured. There was no statistically significant difference in these parameters recorded between control eyes and voriconazole-injected eyes in any concentration groups. Histologic examination with light microscopy did not reveal any retinal abnormality in the eyes with 5 to 25  $\mu\text{g}/\text{mL}$  intravitreal voriconazole. In the eyes with 50  $\mu\text{g}/\text{mL}$  and 500  $\mu\text{g}/\text{mL}$  voriconazole, small foci of retinal necrosis were occasionally observed in the outer retina, especially in the eyes with 500  $\mu\text{g}/\text{mL}$  voriconazole.

**Conclusion:** Our results demonstrate that intravitreal voriconazole of up to 25  $\mu\text{g}/\text{mL}$  causes no ERG change or histologic abnormality in rat retina. This indicates that voriconazole is a safe antifungal agent that may be employed by intravitreal injection in the treatment of fungal endophthalmitis.

*Trans Am Ophthalmol Soc* 2003;101:183-190

## INTRODUCTION

---

Fungal endophthalmitis, although uncommon, remains a serious ophthalmologic challenge owing to its limited available treatments and potentially devastating ocular consequences. Fungal endophthalmitis can be of exogenous origin, such as ocular trauma or surgery, or can be caused by endogenous infection spreading to the eye, such as in immunocompromised patients. Until recently, intravitreal injection of amphotericin B has been the principal treatment for fungal endophthalmitis,<sup>1</sup> although other potential intravitreal antifungal agents have been investigated.<sup>2-4</sup> However, intravitreal amphotericin B, even at low concentration, 4.1  $\mu\text{g}/\text{mL}$  or 8.3  $\mu\text{g}/\text{mL}$  (5  $\mu\text{g}$  or 10  $\mu\text{g}$  injection

into 1.2 mL of rabbit vitreous),<sup>4,5</sup> can cause focal retinal necrosis.<sup>6,7</sup> Furthermore, resistance to amphotericin B has been documented in a variety of human systemic fungal infections.<sup>8</sup> Fluconazole, a triazole agent, has been used systemically as a supplement or alternative to amphotericin B to treat fungal endophthalmitis, since it can reach effective concentration in the vitreous after oral administration,<sup>9,10</sup> but it lacks a broad spectrum of coverage against many of the most commonly encountered organisms found in fungal endophthalmitis.<sup>11,12</sup> Thus ophthalmologists have been very limited in the number of effective antifungal agents, and the current treatment protocols for fungal endophthalmitis are far from optimal.

Recently, a new antifungal agent, voriconazole, has been approved by the Food and Drug Administration for systemic fungal infection. Voriconazole is a second-generation synthetic derivative of fluconazole, and it differs from fluconazole by the addition of a methyl group to the propyl backbone and by the substitution of a triazole moiety with a fluoropyrimidine group. The structural changes in voriconazole result in a higher affinity for the

From the Cullen Eye Institute, Baylor College of Medicine, Houston, Tex (Drs Gao, Pennesi, Shah, Hariprasad, Mieler, Wu, and Holz), and the Department of Cellular Biology and Anatomy, Louisiana State University Health Science Center, Shreveport (Dr Qiao).

\*Presenter.

Bold type indicates AOS member.

fungal 14- $\alpha$ -demethylase, leading to more potent activities.<sup>12</sup> Like fluconazole, voriconazole exerts its effects primarily by inhibiting the fungal cytochrome P450 CYP3A enzyme lanosterol 14- $\alpha$ -demethylase, preventing the conversion of lanosterol to ergosterol. This, in turn, causes depletion of ergosterol, which disrupts the integrity and function of the fungal cell membrane, eventually leading to cell lysis.<sup>13</sup> Voriconazole also inhibits 24-methylene dihydrolanosterol demethylation in certain yeast and filamentous fungi, explaining its increased activities against molds.<sup>14,15</sup>

Many recent studies report that this novel triazole antifungal agent presents potent activity against a broad spectrum of yeast and molds. When compared with amphotericin B, fluconazole, itraconazole, and flucytosine against 6,970 isolates of *Candida* species obtained from over 200 medical centers worldwide, voriconazole and ravuconazole (another new triazole agent) were each more active than amphotericin B against all *Candida* species and were the only agents with good activity against *Candida krusei*.<sup>16</sup> *Candida albicans* is generally the most susceptible yeast, with a voriconazole MIC<sub>90</sub> (the concentration of drug causing a 90% growth inhibition of organisms) of only 0.06  $\mu\text{g/mL}$ , while *Candida glabrata* is the least sensitive, with a MIC<sub>90</sub> of 2.0  $\mu\text{g/mL}$ .<sup>17</sup> Other studies showed that voriconazole was more active than amphotericin B against filamentous fungi, such as *Aspergillus* species, with a mean MIC of 0.19 to 0.58  $\mu\text{g/mL}$ , and *Pseudallescheria boydii*,<sup>18,19</sup> especially invasive *Aspergillus*,<sup>20</sup> with a minimum fungicidal concentration (MFC: at tissue concentrations approximately twice that of MIC) of 0.7 to 1.0  $\mu\text{g/mL}$ .<sup>12</sup> The endemic fungal pathogens *Fusarium* species, *Histoplasma capsulatum*, *Coccidioides immitis*, *Blastomyces dermatitidis*, *Penicillium marneffei*, *Scedosporium apiospermum*, *Paracoccidioides brasiliensis*, and *Cryptococcus neoformans*, and the dermatophytes are also fully susceptible to voriconazole.<sup>12,21</sup> Voriconazole also has good activity against those fungi that are resistant to the other commonly used antifungal agents, such as amphotericin B and fluconazole.<sup>13,22,23</sup> Voriconazole does not appear to have cross-resistance with amphotericin B, likely because of the different sites of action of the two agents.<sup>24</sup>

Since the treatment for fungal endophthalmitis is very limited and voriconazole shows potent broad-spectrum coverage for fungal infections, this study was designed to examine whether voriconazole could be safely used as an intravitreal agent in the treatment of fungal endophthalmitis. Rats were used as animal models in our study. Intravitreal voriconazole injections were performed, and retinal function and anatomy were subsequently examined using electroretinographic and histologic studies.

## MATERIALS AND METHODS

### ANIMALS

Sprague-Dawley albino rats 6 to 7 weeks old (approximately 250 g) were obtained from Charles River Laboratories (Wilmington, Mass). Animals were fed ad libitum with Purina lab chow and water, and room lighting consisted of a 12-hour light/12-hour dark cycle. The experiments were carried out in accordance with ARVO principles of animal maintenance and care and were approved by the institutional review board at Baylor College of Medicine, Houston, Tex.

### VORICONAZOLE INTRAVITREAL INJECTION

Animals were anesthetized with intraperitoneal injections of a solution containing ketamine (95 mg/mL) and xylazine (5 mg/mL) in a dosage of 0.2 mL/100 g of body weight. Proparacaine hydrochloride 0.5% (Alcon Labs, Inc, Forth Worth, Tex) was used for additional topical anesthesia. Ofloxacin ophthalmic solution 0.3% (Allergan, Inc, Irvine, Calif) was applied to the ocular surface before injection, and bacitracin ophthalmic ointment, 500 units/g (E Fougera & Co, Melville, NY), after injection, to prevent infection. Voriconazole IV (Vfend), a white lyophilized powder, was obtained from Pfizer, Inc. Based on a study of microbial keratitis caused by a variety of fungal pathogens, the MIC of voriconazole is 0.5  $\mu\text{g/mL}$  to 5.0  $\mu\text{g/mL}$ .<sup>25</sup> Since this is a retinal toxicity study, we chose to use 5  $\mu\text{g/mL}$  as MIC, although it is much higher than those in the literature (see "Introduction"). Voriconazole solutions were serially diluted with balanced salt solution (BSS) (Alcon Labs, Inc) so that the final intravitreal concentrations were 5.0  $\mu\text{g}$ , 10  $\mu\text{g}$ , 25  $\mu\text{g}$ , 50  $\mu\text{g}$ , and 500  $\mu\text{g/mL}$  (1, 2, 5, 10, and 100 fold of MIC, respectively) based on prior data that adult rat vitreous volume is  $56 \pm 4 \mu\text{L}$ .<sup>26</sup> Serially diluted voriconazole solutions of 6 mL were injected intravitreally into rat eyes under a dissecting microscope using a Hamilton micro-injector (Hamilton Co, Reno, Nev) (N=3 for each concentration group). A 30-gauge needle was first used to make a punch incision 0.5 mm posterior to the temporal limbus, and the Hamilton needle was then inserted through the incision, approximately 1.5 mm deep, angled toward the optic nerve until the tip of needle was visualized in the center of vitreous. BSS of equal volume (6  $\mu\text{L}$ ) was injected into the fellow eyes of each animal as controls. Following intravitreal injection, animals were kept under ambient light on a 12-hour light/dark schedule. Three weeks after injection, animals were processed for electroretinographic recordings and subsequent retinal histologic examinations.

### ELECTRORETINOGRAM RECORDINGS

Prior to testing, rats were allowed to dark adapt overnight.

Under dim red light, rats were anesthetized with a solution of ketamine (95 mg/mL) and xylazine (5 mg/mL). Pupils were dilated with a single drop of 0.5% mydracil and 2.5% phenylephrine. A drop of 0.5% proparacaine hydrochloride was applied for corneal anesthesia. Rats were placed on a heating pad maintained at 39°C, inside a Ganzfeld dome coated with highly reflective white paint (Munsell paint, New Windsor, NY). A small amount of 2.5% methylcellulose gel was applied to the eye, and a platinum electrode was placed in contact with the center of the cornea. Similar platinum reference and ground electrodes were placed in the forehead and tail, respectively. After placement in the dome, rats were kept in complete darkness for several minutes. Signals were amplified with a Grass P122 amplifier (bandpass, 0.1 Hz to 1,000 Hz). Data were acquired with National Instruments Lab-PC DAQ board (sampling rate, 10,000 Hz). Traces were averaged and analyzed with custom software written in Matlab. Flashes were calibrated in a manner similar to that described<sup>27</sup> and are detailed elsewhere.<sup>28</sup> Flashes for scotopic b-wave measurements were generated by a Grass PS-33+ photostimulator. Light was spectrally filtered with a 500-nm interference filter (Edmund Scientific). Flashes varied in intensity from  $-3.85$  to  $-0.76$  log scotopic candela-sec/m<sup>2</sup>. For analysis of the a wave and cone function, we used a 1,500-W Novatron xenon flash lamp, which produced approximately 2.92 log scotopic candela-sec/m<sup>2</sup>.

#### RETINAL HISTOLOGY

Following electroretinographic tests, animals were euthanized with an overdose of intraperitoneal ketamine and xylazine. The eye was enucleated, an incision was made in the cornea, and the eye was fixed immediately in 4% formaldehyde in 0.1 M phosphate buffer (pH, 7.4). After 15 minutes in the fixative, the lens was removed and the eye was cut along the cornea-optic nerve axis into halves. Gross examinations of the tissues were performed. Tissues were further fixed overnight in 4% paraformaldehyde and 0.5% glutaraldehyde in 0.1 M phosphate buffer (pH, 7.4). Tissues were then embedded in paraffin, sectioned at a thickness of 6  $\mu$ m, and stained with hematoxylin-eosin. Light microscope was used for histologic examinations.

#### RESULTS

##### ELECTRORETINOGRAM

The scotopic b wave is a measurement of the extracellular field potential that primarily arises from rod bipolar cells in response to dim flashes of light.<sup>29</sup> Figure 1, top row, shows scotopic b-wave responses to increasing intensities of flashed light. The relationship between scotopic

b-wave amplitude and intensity can be modeled using a hyperbolic saturation function (Naka-Rushton function). This model yields two parameters,  $b_{\max}$ , scot and  $I_{0.5}$ , representing the maximum b-wave amplitude and the intensity that provides half saturation. In eyes without any injection,  $b_{\max}$  measured  $790 \pm 100$  mV (n=4) and  $I_{0.5}$  measured  $-3.01 \pm 0.06$  log scotopic candela-sec/m<sup>2</sup>. In eyes with BSS injection as control,  $b_{\max}$  and  $I_{0.5}$  were basically the same as the eyes without any injection. In eyes with 5 mg/mL intravitreal voriconazole,  $b_{\max}$  measured  $685 \pm 70$  mV (n=2) and  $I_{0.5}$  measured  $-2.93 \pm 0.09$  log scotopic candela-sec/m<sup>2</sup>. In eyes with 50 mg/mL intravitreal voriconazole,  $b_{\max}$  measured  $680 \pm 110$  mV (n=3) and  $I_{0.5}$ ,  $-2.96 \pm 0.04$  log scotopic candela-sec/m<sup>2</sup>. In eyes with 500 mg/mL voriconazole,  $b_{\max}$  measured  $700 \pm 90$  mV (n=3) and  $I_{0.5}$  measured  $-2.89 \pm 0.06$  log scotopic candela-sec/m<sup>2</sup>. There was no statistical difference in  $b_{\max}$  and  $I_{0.5}$  between control eyes and any of the voriconazole-injected eyes using the two-way Student *t* test.

To more directly characterize rod photoreceptor function, we measured the scotopic a wave of the electroretinogram (ERG), which in the rat arises almost exclusively from the rod photoreceptors.<sup>29</sup> Figure 1, bottom row, shows the response to an intense flash, which saturated the rod photoreceptors. The saturated a-wave amplitude from control eyes measured  $380 \pm 65$  mV (n=4). The saturated a-wave amplitudes for the eyes with 5, 50, and 500 mg/mL intravitreal voriconazole were  $305 \pm 10$  (n=3),  $365 \pm 84$  (n=2), and  $355 \pm 15$  mV (n=3), respectively. There was no statistical difference in scotopic a-wave response between control eyes and any voriconazole-injected eyes using the two-way Student *t* test. Even in eyes with 500  $\mu$ g/mL intravitreal voriconazole (100-fold MIC), the ERGs showed little difference compared with the control eyes. In one of the voriconazole-injected eyes (5  $\mu$ g/mL), a cataract developed as a result of the needle injury during injection. The ERG showed mild depression due to medium opacity in the eye. These data were excluded from analysis.

##### RETINAL HISTOLOGY

Gross examination of eye specimens showed no retinal hemorrhages or signs of infection in any voriconazole-injected or control eyes. Histologic examination with light microscopy did not reveal any retinal abnormality in the eyes injected with BSS as controls (pictures not shown). In eyes injected with intravitreal voriconazole from 5.0  $\mu$ g to 25  $\mu$ g/mL (1- to 5-fold MIC), no abnormality could be observed in any area of retina (Figure 2A). In the eyes injected with 50  $\mu$ g/mL intravitreal voriconazole (10-fold MIC), small focal retinal necroses were occasionally noticed in the outer retina (Figure 2B). In these necrotic

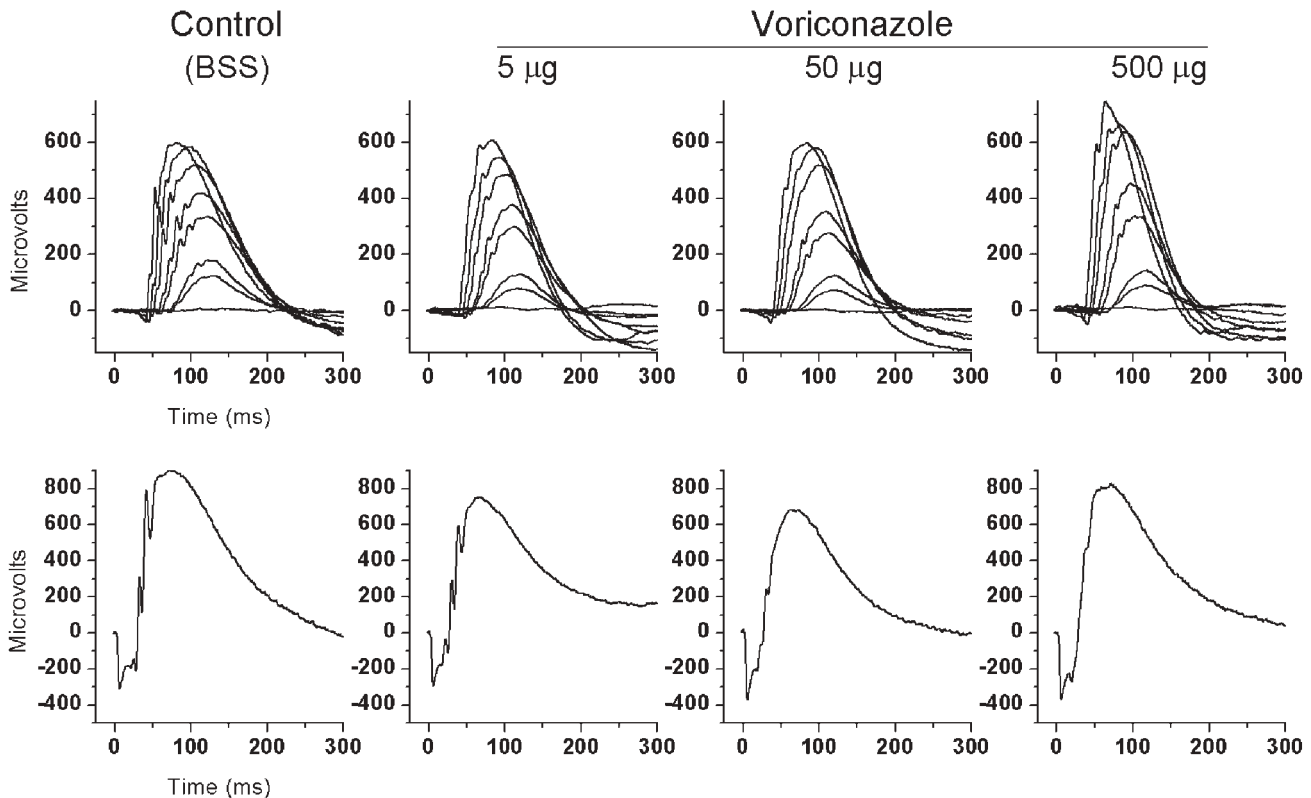


FIGURE 1

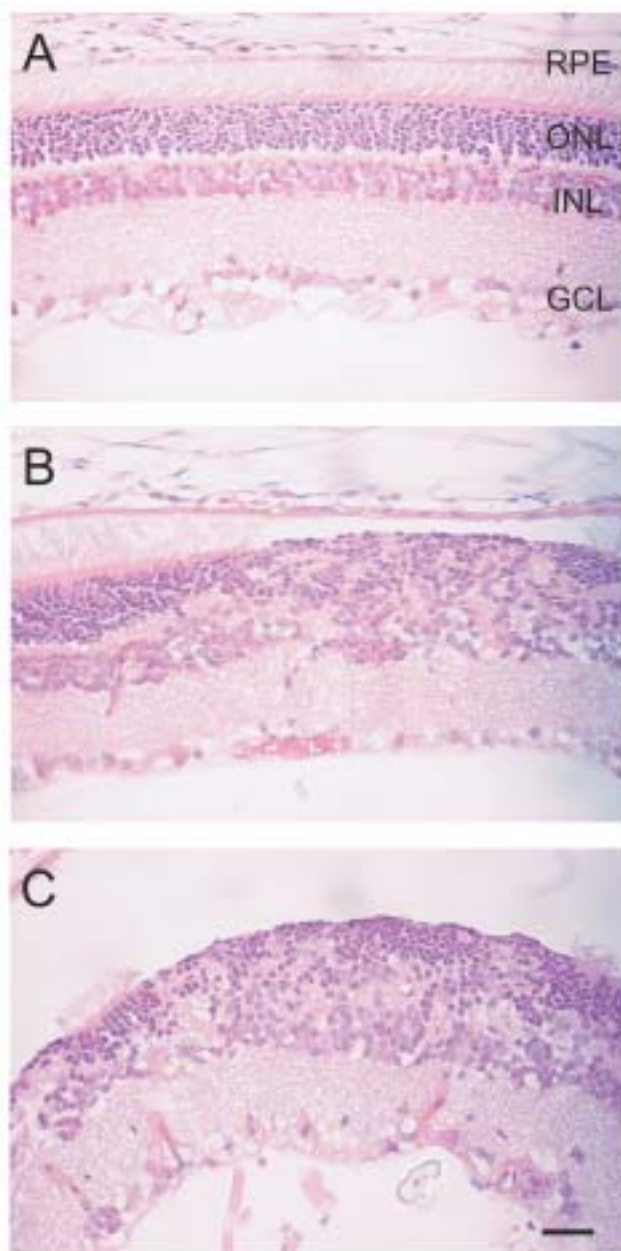
Electroretinogram recordings from rat eyes 3 weeks following intravitreal injection of BSS (control) or voriconazole (5, 50, and 500 µg/mL). Top row, Scotopic b-wave recordings to a series of flashes ranging in intensity from  $-3.85$  to  $-0.76$  log scotopic candela-sec/m<sup>2</sup>. Bottom row, Saturated a-wave responses to a bright flash of 2.92 log scotopic candela-sec/m<sup>2</sup>. There was no significant difference in electroretinograms recorded between the control and any voriconazole groups. BSS, balanced salt solution.

areas, photoreceptor layer and inner nuclear layer were disorganized. Photoreceptor degeneration was evident, and photoreceptor inner and outer segments were absent. The ganglion cell layer appeared intact. In the eyes injected with 500 µg/mL intravitreal voriconazole (100-fold MIC), more focal retinal necrotic areas were found with more obvious photoreceptor degeneration and disorganization of photoreceptor and inner nuclear layers (Figure 2C). Focal retinal detachment was noticed in these necrotic areas. Inflammatory cells were also noticed in these focal retinal areas with choroidal congestion present. In the other area where focal necrosis was not observed, retina appears normal with light microscopy examination.

## DISCUSSION

Our studies demonstrate that voriconazole did not cause retinal toxicity on either electroretinographic or histologic studies when intravitreal concentrations were 25 µg/mL or less. When the voriconazole concentration reached 50 µg/mL, focal retinal necrosis was occasionally noticed

on histologic examination, but the ERG was not affected, since ERG is a mass electrical response from the whole retina, and focal necrosis may not cause ERG abnormalities. Although there may be species difference in retinal reaction to voriconazole, our results provide a solid reference level for its retinal toxicity. When these results are transferred on human eyes, voriconazole of 100 µg can be injected into human vitreous without causing long-term electroretinographic or histologic abnormalities based on the fact that average human vitreous volume is 4 mL. Thus voriconazole is much safer to retina than amphotericin B, since very low dosage of intravitreal amphotericin B (4.1 to 8.3 µg/mL) causes focal retinal necrosis on rabbit studies.<sup>7</sup> Since voriconazole is superior or at least similar to amphotericin B against common and rare yeast and mold infections,<sup>14,19</sup> we suggest that voriconazole should be considered as a first-line intravitreal agent for treatment of fungal endophthalmitis. A recent case report showed that endophthalmitis caused by *Fusarium solani* was successfully treated with intracameral, topical, and systemic voriconazole when it failed to respond to amphotericin B, fluconazole, or itraconazole.<sup>30</sup>



**FIGURE 2**

Histology of retina of rat eyes 3 weeks after intravitreal injection of balanced salt solution (BSS) (control) and voriconazole. Retinas were normal in eyes injected with BSS (not shown). A, In eyes with intravitreal voriconazole from 5.0  $\mu\text{g}$  to 25  $\mu\text{g}/\text{mL}$ , no abnormality could be observed in retina. B, In eyes with 50  $\mu\text{g}/\text{mL}$  voriconazole, small focal retinal necroses were occasionally noticed in the outer retina. Notice photoreceptor layer and inner nuclear layer disorganization, photoreceptor degeneration, and missing photoreceptor inner and outer segments. The ganglion cell layer appeared intact. C, In the eyes with 500  $\mu\text{g}/\text{mL}$  voriconazole, more obvious photoreceptor degeneration and disorganization of photoreceptor and inner nuclear layers were present. Notice focal retinal detachment. RPE, retinal pigment epithelium; ONL, outer nuclear layer; INL, inner nuclear layer; GCL, ganglion cell layer. Scale bar = 100  $\mu\text{m}$ .

When voriconazole was used for systemic fungal infections through either oral or intravenous administration, adverse effects were observed, including transient visual disturbance, hepatotoxicity, and skin reactions. The most frequent side effect is transient visual disturbance, described as enhanced light perception, blurred vision, photophobia, or color vision changes. These visual events occurred in 23% to 35% of patients,<sup>12</sup> generally within 30 minutes of dosing, and most frequently during the first week of therapy. These events were usually mild and resolved within 30 minutes. Electroretinographic study has shown that retina is the site of these events, with decreased amplitude of ERG waveforms in human and dogs.<sup>31</sup> Histologic examination showed no alterations in the retina or visual pathways in dogs as a result of voriconazole administration. No human histopathology has been found, and ocular examination has not detected any lesions.<sup>12</sup> No potential mechanism of this visual disturbance has been described.<sup>14</sup> It is possible that rats might experience similar early transient visual disturbance in our studies, but this would be very difficult to determine, since visual changes have to be tested subjectively. However, we did not observe any electroretinographic or histologic abnormalities 3 weeks after intravitreal voriconazole (<25  $\mu\text{g}/\text{mL}$ ) injection. Thus, our results confirm previous studies of systemic voriconazole that found that electroretinographic changes, if any, occur in early stages, are transient, do not last more than 3 weeks after voriconazole administration, and do not cause permanent damage to the retina.

Pharmacokinetic studies showed that tissue concentration of voriconazole after systemic administration was highest in liver, followed by the retina.<sup>12</sup> Based on this fact, we studied oral voriconazole penetration to human vitreous and aqueous humor to determine if systemic voriconazole can be used for treatment of fungal endophthalmitis. After two dosages of 400 mg oral voriconazole, vitreous and aqueous humor specimens of 14 patients were obtained from vitrectomy and analyzed with high-performance liquid chromatography. Intravitreal and intracameral concentrations of voriconazole were  $0.81 \pm 0.31 \mu\text{g}/\text{mL}$  and  $1.13 \pm 0.57 \mu\text{g}/\text{mL}$ , respectively, and were 38.1% and 53.0% of plasma concentration, respectively.<sup>32</sup> Since the MIC<sub>90</sub> of voriconazole for most of the yeast and molds is low, systemic voriconazole is a good choice for endogenous fungal endophthalmitis. For those systemic fungal infections known to be sensitive to voriconazole, oral or intravenous administration can be used to treat both the systemic infection and endophthalmitis. Supplementary intravitreal injection of the drug can be used if needed. For those fungi, such as *Fusarium* species, in which MIC is higher than the intraocular level achieved by systemic administration, intravitreal voriconazole injection is an excellent choice for treatment. Since

voriconazole is metabolized primarily in the liver, by cytochrome P450 isoenzymes CYP2C19, CYP2Cp, and CYP3A4,<sup>12</sup> some patients may be limited from systemic voriconazole administration due to drug-drug interactions. Also, hepatotoxicity may prevent some patients from taking voriconazole systemically. Under these circumstances, intravitreal injection should be considered. When the infection is due to trauma or surgery, especially when surgery such as vitrectomy is needed, intravitreal voriconazole is the treatment of choice.

## REFERENCES

- Brod RD, Clarson JG, Flynn HW, et al. Endogenous fungal endophthalmitis. In: Tasman W, ed. *Duane's Clinical Ophthalmology*. Philadelphia: JB Lippincott, 1994.
- Shahsavari M, Peyman GA, Niesman MR. Retinal toxicity and in vitro efficacy study of cilofungin (LY121019). *Ophthalmic Surg* 1990;21:726-728.
- Dunlap WA, Karacorlu M, Peyman GA, et al. Retinal toxicity of intravitreally injected faeriefungin. *Ophthalmic Surg* 1994;25:303-306.
- Serracarbassa PD, Peyman GA, Liang C, et al. Toxicity and efficacy of intravitreal injection of spartanamicin B in the treatment of *Candida* endophthalmitis. *Int Ophthalmol* 1998;22:53-58.
- Lazar M, Ganor E, Nemet P, et al. The effect of experimental glaucoma on vitreous volume. *Metab Pediatr Syst Ophthalmol* 1982;6:347-348.
- Axelrod AJ, Peyman GA, Apple DJ. Toxicity of intravitreal injection of amphotericin B. *Am J Ophthalmol* 1973;76:578-583.
- Baldinger J, Doft BH, Burns SA, et al. Retinal toxicity of amphotericin B in vitrectomised versus non-vitrectomised eyes. *Br J Ophthalmol* 1986;70:657-661.
- Gallis HA, Drew RH, Pickard WW. Amphotericin B: 30 years of clinical experience. *Rev Infect Dis* 1990;12:308-329.
- O'Day DM, Foulds G, Williams TE, et al. Ocular uptake of fluconazole following oral administration. *Arch Ophthalmol* 1990;108:1006-1008.
- Christmas NJ, Smiddy WE. Vitrectomy and systemic fluconazole for treatment of endogenous fungal endophthalmitis. *Ophthalmic Surg Lasers* 1996;27:1012-1018.
- Wellington M, Gigliotti F. Update on antifungal agents. *Pediatr Infect Dis J* 2001;20:993-995.
- Ghannoum MA, Kuhn DM. Voriconazole—better chances for patients with invasive mycoses. *Eur J Med Res* 2002;7:242-256.
- Ghannoum MA, Rice LB. Antifungal agents: mode of action, mechanisms of resistance, and correlation of these mechanisms with bacterial resistance. *Clin Microbiol Rev* 1999;12:501-517.
- Sabo JA, Abdel-Rahman SM. Voriconazole: a new triazole antifungal. *Ann Pharmacother* 2000;34:1032-1043.
- Sanati H, Belanger P, Fratti R, et al. A new triazole, voriconazole (UK-109,496), blocks sterol biosynthesis in *Candida albicans* and *Candida krusei*. *Antimicrob Agents Chemother* 1997;41:2492-2496.
- Pfaller MA, Messer SA, Hollis RJ, et al. In vitro activities of ravuconazole and voriconazole compared with those of four approved systemic antifungal agents against 6,970 clinical isolates of *Candida* spp. *Antimicrob Agents Chemother* 2002;46:1723-1727.
- Pfaller MA, Messer SA, Hollis RJ, et al. In vitro susceptibilities of *Candida* bloodstream isolates to the new triazole antifungal agents BMS-207147, Sch 56592, and voriconazole. *Antimicrob Agents Chemother* 1998;42:3242-3244.
- Marco F, Pfaller MA, Messer SA, et al. Antifungal activity of a new triazole, voriconazole (UK-109,496), compared with three other antifungal agents tested against clinical isolates of filamentous fungi. *Med Mycol* 1998;36:433-436.
- Espinel-Ingroff A, Boyle K, Sheehan DJ. In vitro antifungal activities of voriconazole and reference agents as determined by NCCLS methods: review of the literature. *Mycopathologia* 2001;150:101-115.
- Maesaki S, Iwakawa J, Higashiyama Y, et al. Antifungal activity of a new triazole, voriconazole (UK-109496), against clinical isolates of *Aspergillus* spp. *J Infect Chemother* 2000;6:101-103.
- Kappe R. Antifungal activity of the new azole UK-109, 496 (voriconazole). *Mycoses* 1999;42(suppl 2):83-86.
- Sutton DA, Sanche SE, Revankar SG, et al. In vitro amphotericin B resistance in clinical isolates of *Aspergillus terreus*, with a head-to-head comparison to voriconazole. *J Clin Microbiol* 1999;37:2343-2345.
- White TC, Marr KA, Bowden RA. Clinical, cellular, and molecular factors that contribute to antifungal drug resistance. *Clin Microbiol Rev* 1998;11:382-402.
- Abraham OC, Manavathu EK, Cutright JL, et al. In vitro susceptibilities of *Aspergillus* species to voriconazole, itraconazole, and amphotericin B. *Diagn Microbiol Infect Dis* 1999;33:7-11.
- Shah KB, Wu TG, Wilhelmus KR, et al. Activity of voriconazole against corneal isolates of *Scenedosporium apiospermum*. *Cornea* 2003;22:33-36.
- Berkowitz BA, Lukaszew RA, Mullins CM, et al. Impaired hyaloidal circulation function and uncoordinated ocular growth patterns in experimental retinopathy of prematurity. *Invest Ophthalmol Vis Sci* 1998;39:391-396.
- Lyubarsky AL, Pugh EN. Recovery phase of the murine rod photoresponse reconstructed from electroretinographic recordings. *J Neurosci* 1996;16:563-571.
- Howes KA, Pennesi ME, Sokal I, et al. GCAP1 rescues rod photoreceptor response in GCAP1/GCAP2 knockout mice. *EMBO J* 2002;21:1545-1554.
- Pugh Jr EN, Falsini B, Lyubarsky AL. The origin of the major rod- and cone-driven components of the rodent electroretinogram, and the effect of age and light rearing history on the magnitudes of these components. In: Williams TP, Thistle AB, eds. *Photostasis and Related Topics*. New York: Plenum, 1998.
- Reis A, Sundmacher R, Tinteln K, et al. Successful treatment of ocular invasive mould infection (fusariosis) with the new antifungal agent voriconazole. *Br J Ophthalmol* 2000;84:932-933.

31. Tomaszewski K, Purkins L. The pharmacokinetics (PK) and safety of sulfobutylether-B-cyclodextrans. In: Program and abstracts of American Society for Microbiology 41st Interscience Conference on Antimicrobial Agents and Chemotherapy; 2001, Chicago, Ill. Abstract A-23.
32. Hariprasad SM, Mieler WF, Holz ER, et al. Determination of vitreous, aqueous, and plasma concentration of orally administered voriconazole in humans. *Arch Ophthalmol*. In press

## DISCUSSION

---

DR GEORGE W. BLANKENSHIP. During the past few years, major advances have been made in the treatment of endophthalmitis. The collaborative Vitrectomy for Endophthalmitis Clinical Trial<sup>1,2</sup> clearly showed the value of intravitreal antibiotics, and clarified the indications for pars plana vitrectomy and biopsy of the vitreous obtained by small needle aspiration for endophthalmitis following cataract surgery. Important improvements have also been made with the development and availability of new pharmacological agents to effectively and safely treat infections caused by a wide range of organisms.

Voriconazole is a relatively new antifungal medication developed by modifying the molecular structure of Fluconazole. It has been successfully used systemically to treat a wide spectrum of yeast and mold infections. The authors recognized its additional potential value as an intravitreal medication and have shown that it is relatively safe without ERG or histologic changes in the retina at doses of up to 25 micrograms per milliliter. The greater volume of the human vitreous cavity compared to the rat model used in their laboratory research should further increase the safety of its intravitreal use.

Amphotericin B has been the most frequently used antifungal medication for endophthalmitis, but can cause retinal necrosis even at relatively low concentrations. In addition, an increasing number of types of molds and yeasts are developing resistance to Amphotericin, which further threatens its effectiveness for fungal endophthalmitis.

The continued identification, development, and availability of new treatments for endophthalmitis that are safe with relatively low risks of systemic and ocular side effects and toxicity is obviously important. The authors are congratulated on their important contributions and encouraged to continue their collaborative research.

## REFERENCES

---

1. The Endophthalmitis Vitrectomy Study. Doft BH. *Arch Ophthalmol* 1991;109:1060-1061.
2. Optimal Management of Postoperative Endophthalmitis and Results of the Endophthalmitis Vitrectomy Study. Doft BH, Barza M. *Curr Opin Ophthalmol* 1996;7:84-94.

DR WILLIAM F. MIELER. Is the rat model appropriate? We never quite fully know for sure. There certainly have been previous studies done with other antibiotics and antifungal agents in rats and rabbits: for the most part there seems to be quite good correlation with toxicity and potential effectiveness in humans. Time will tell if our model has any shortcomings or if it appears to be reasonable to apply our data to humans.

Have there been any clinical applications of this agent at the present time? Yes, there have been two cases of which I'm aware, though neither case has yet been reported in the literature. One case involved a subtenon injection of voriconazole for a case of *Fusarium* scleritis which was unresponsive to amphotericin. Additionally, there has been one case of an intravitreal injection of voriconazole in a patient with *Fusarium* endophthalmitis, unresponsive to conventional therapy. Voriconazole was given at a dosage of 50 microns, with a second repeat injection performed approximately one week later. These are the only cases where there has been direct human ocular application of voriconazole at the present time, though I anticipate significant usage in the near future.

