

# GRADED FULL-THICKNESS ANTERIOR BLEPHAROTOMY FOR UPPER EYELID RETRACTION

---

BY **Victor M. Elnor MD PhD**,<sup>\*</sup> *Adam S. Hassan MD*, AND **Bartley R. Frueh MD**

## ABSTRACT

*Purpose:* A chief morbidity of Graves' eye disease (GED) is upper lid retraction that results in exposure keratopathy and cosmetic deformity. This study was conducted to assess the efficacy of graded anterior blepharotomy to treat upper lid retraction.

*Methods:* Fifty eyelids of 32 patients with GED-associated upper lid retraction causing symptomatic ocular exposure were treated with graded, transcutaneous, full-thickness, anterior blepharotomy. Preoperative and postoperative ocular exposure symptoms, upper lid position, lagophthalmos, and keratopathy were compared.

*Results:* At an average of  $8.5 \pm 8.1$  months (range, 2 to 35 months) follow-up, more than 90% of preoperative symptoms resolved or improved. Upper eyelid position ( $P < .00001$ ), lagophthalmos ( $P < .0001$ ), and keratopathy ( $P < .01$ ) were significantly improved. Mild contour abnormalities (all  $\leq 1$  mm) occurred in 7 of 50 eyelids. Eyelid crease recession or asymmetry occurred in 4 of 22 patients with postoperative lid crease measurements. Complications of ptosis, wound dehiscence, and full-thickness hole each occurred once. The average time for performing the procedure was  $31.5 \pm 8.9$  minutes per eyelid.

*Conclusions:* Graded anterior blepharotomy for upper lid retraction is a safe and highly effective surgical treatment for symptomatic GED-associated upper eyelid retraction. This technique achieves excellent functional and cosmetic outcomes.

*Trans Am Ophthalmol Soc* 2003;101:67-76

## INTRODUCTION

---

Upper eyelid retraction is a common manifestation of Graves' eye disease (GED).<sup>1,2</sup> Lid retraction may result in exposure keratopathy and disturbing symptoms, including blurred vision, photophobia, foreign body sensation, burning, and reactive tearing. Contributing to ocular exposure are impaired excursion of eyelid blink and lagophthalmos.<sup>1,3</sup> In addition, the characteristic lid retraction of GED results in significant cosmetic deformity and often causes discomfort due to perceived tightness.

Surgical treatment for upper eyelid retraction has included numerous procedures, such as Müller muscle recession or excision,<sup>4,5</sup> anterior or posterior levator recession with or without adjustable sutures,<sup>4,6-10</sup> marginal myotomy,<sup>11</sup> and placement of natural or synthetic spacer grafts.<sup>12-14</sup> These surgical techniques require extensive dissections that may contribute to unpredictable outcomes of postoperative ptosis, contour abnormalities, eyelid thickening, lid crease recession, and undercorrection.

In 1965, Henderson<sup>4,15</sup> described a transconjunctival

partial-thickness blepharotomy consisting of a supratarsal conjunctival incision followed by Müller muscle transection with or without levator aponeurotomy. Other investigators found this rapid technique to be useful in the management of mild upper eyelid retraction in the absence of abnormal eyelid contour.

In the 1990s, Leo Koornneef developed a novel, rapid transcutaneous, graded blepharotomy technique. On June 10, 1999, Koornneef presented his method at the University of Michigan. He reported his method to be effective and to yield predictable results, even in patients with severe eyelid retraction. However, owing to his untimely death, his results have remained unpublished. In this study, we evaluated our results using Koornneef's technique for the treatment of upper eyelid retraction. This report describes the beneficial effects of graded full-thickness anterior blepharotomy on functional and cosmetic parameters in patients with symptomatic upper eyelid retraction.

## MATERIALS AND METHODS

---

### CLINICAL EVALUATION

Included in this study are patients with GED who presented to the Eye Plastic and Orbital Surgery Service

From the Department of Ophthalmology, University of Michigan, Ann Arbor.

<sup>\*</sup>Presenter.

Bold type indicates **AOSS** member.

of the University of Michigan Kellogg Eye Center and were operated upon (V.M.E. and B.R.F.) between August 1999 and July 2002 for treatment of symptomatic ocular complications of upper eyelid retraction. Presence and severity of ocular symptoms including discomfort, tearing, asymmetry, photophobia, and pain/burning were documented preoperatively and postoperatively. Also noted were patient age, time elapsed from the onset of GED, laterality of involvement, and surgical time.

Preoperative and postoperative superficial punctate keratopathy (SPK) was graded from 0 to 4+ as follows: 0 = none, 1 = mild, 2 = moderate, 3 = severe, 4 = epithelial ulceration. The percentage of corneal surface involved with SPK multiplied by the SPK grade was used to derive a corneal exposure index (CEI). Preoperative and postoperative position of the upper eyelid was measured in millimeters from the midpupil to the upper eyelid margin with the eye in primary gaze and with the coronal plane of the patient's head perpendicular to the floor. Eyelids were divided into groups according to the severity of upper eyelid retraction as measured by distance of the upper eyelid margin from the center of the pupil (severe, lid height  $\geq 7$  mm; moderate, lid height,  $>5$  mm to  $<7$  mm; mild, lid height  $\leq 5$  mm). Lagophthalmos, measured during gentle eyelid closure, and lid crease height were also measured in millimeters.

To be considered for surgical rehabilitation, patients had to have stable upper eyelid retraction for greater than 6 months, except for one patient, who had 2 months of stability. Indications for surgery included upper eyelid retraction with symptomatic exposure keratopathy or reflex tearing, whether or not lagophthalmos was present. Two surgeons (V.M.E. and B.R.F.) performed all surgical procedures.

#### SURGICAL METHOD

After informed consent was obtained, transcutaneous, graded full-thickness anterior blepharotomies were performed. After marking for symmetric upper eyelid crease incisions, anesthesia was accomplished with intravenous sedation and local infiltration with bupivacaine 0.5% mixed in equal parts with lidocaine 1% with epinephrine 1:100,000 or with epinephrine supplementation to 1:50,000 as described by Fante and Elnor.<sup>16</sup> The skin was incised in the relevant portion (central, medial, or lateral) of the marked crease. Subsequent dissection through the orbicularis oculi muscle for the length of the incision exposed the levator aponeurosis inferior to its confluence with the orbital septum near the superior border of the tarsal plate. The levator aponeurosis, Müller's muscle, and conjunctiva were then incised in the area of greatest retraction, creating a full-thickness blepharotomy. The dissection usually was initiated at the

junction of the lateral and central thirds of the upper eyelid. The full-thickness blepharotomy was then extended medially and laterally in a graded fashion based on the unseated patient's lid height and contour while seated and in primary gaze. The upper lid was recessed to obtain a final postoperative lid height between 2 and 4 mm, depending on the severity of exposure symptoms, or the height of the other eyelid in unilateral cases. The goal was to reduce the signs and symptoms of ocular exposure while preserving the full binocular visual field.

In cases with temporal flare, full-thickness dissection was performed laterally to the superior crus of the lateral canthal ligament, cutting the lateral horn of the levator aponeurosis inferior to the lacrimal gland ducts. When extensive medial dissection resulted in flattening of the upper lid contour, a single 6-0 polyglactin mattress suture was placed between the levator aponeurosis and tarsal plate in the flattened area to restore a desirable upper lid contour. Limited bipolar cautery was used for hemostasis. The procedure was completed by a simple skin closure with continuous 6-0 nylon or 6-0 polypropylene suture, or interrupted 6-0 fast-absorbing plain gut suture. No additional procedures were performed. No temporary tarsorrhaphy or traction sutures were placed.

All groups of data are expressed as averages  $\pm$  SD. Statistical significance of differences between preoperative and postoperative groups of measurements was determined using Student's two-tailed *t* test. Differences between groups were considered to be statistically significant for  $P < .05$ .

#### RESULTS

The Koornneef graded full-thickness anterior blepharotomy was performed on 50 eyelids of 32 patients with an average follow-up time of  $8.5 \pm 8.1$  months (range, 2 to 35 months). Thirteen patients had less than 6 months of follow-up (4, 3, 3, and 3 patients for 5, 4, 3, and 2 months, respectively). The average patient age was  $52 \pm 14$  years (range, 20 to 82 years); there were 30 women and 2 men. Duration of GED averaged  $6.8 \pm 6.9$  years.

The most common presenting symptoms of GED-associated upper eyelid retraction were discomfort and tearing due to the effects of ocular exposure and asymmetry of lid height (Table I). Postoperatively, 93% of patients' initial symptoms were resolved or improved. Symptoms remained unchanged only in those patients who had intercurrent factors, namely, dryness due to radiation therapy or lower eyelid retraction or asymmetry due to postoperative ptosis.

The upper eyelid height was improved by surgery in all 50 eyelids (Figure 1, Table II). The difference between preoperative and postoperative height was highly

Graded Full-Thickness Anterior Blepharotomy for Upper Eyelid Retraction

TABLE I: SYMPTOMS OF GED RETRACTION AND EFFECT OF BLEPHAROTOMY IN 32 PATIENTS

PREOPERATIVE SYMPTOMS	NO. OF PATIENTS	RESOLVED	POSTOPERATIVE SYMPTOMS	
			PARTIAL IMPROVEMENT	UNCHANGED
Discomfort (including dryness and foreign body sensation)	17	10 (59%)	6 (35%)	1 (6%) <sup>°</sup>
Tearing	16	5 (31%)	9 (56%)	2 (13%) <sup>†</sup>
Asymmetry	11	10 (91%)	0	1 (9%) <sup>‡</sup>
Photophobia	6	6 (100%)	0	0
Pain/burning	7	4 (57%)	3 (43%)	0
Total		35 (61%)	18 (32%)	4 (7%)

<sup>°</sup>Radiotherapy-induced dryness.

<sup>†</sup>One patient, radiotherapy-induced dryness; 1 patient, lower lid retraction.

<sup>‡</sup>One patient, postoperative ptosis.

statistically significant regardless of the degree of preoperative retraction severity (severe, moderate, and mild all with  $P < .00001$ ; Table II; Figure 2). The final postoperative eyelid heights were not statistically different regardless of whether initial retraction severity was severe, moderate, or mild (Figure 2). However, the final lid heights obtained following recession in patients with severe retraction were more variable, with a standard deviation of 1.29 (Table II). This resulted in fewer patients in the severe group (53%) with final lid heights in the target range of 2 to 4 mm when compared to those in the moderate (81%) and mild (93%) groups (Table II). Postoperative eyelid heights for patients followed for 6 months or more after surgery ( $3.22 \pm 0.84$  mm) did not differ significantly ( $P = .3248$ ) from those of patients with follow-up ranging from 2 to 6 months ( $3.48 \pm 0.94$  mm).

Preoperative lagophthalmos was present in 30 eyelids. The difference between preoperative and postoperative lagophthalmos was statistically significant for eyelids with all degrees of preoperative eyelid retraction (severe,  $P < .001$ ; moderate,  $P < .001$ ; mild,  $P < .01$ ) (Figure 3) or preoperative lagophthalmos, regardless of the amount ( $P < .00001$ ) (Figure 4). There was no statistical significance when residual postoperative lagophthalmos was compared among eyelids with varying degrees of preoperative retraction severity or lagophthalmos. Lagophthalmos resolved in 13 of 16 eyes (81%) with preoperative lagophthalmos  $\leq 1.0$  mm and in 10 of 14 eyes (71%) with preoperative lagophthalmos  $\geq 1.5$  mm. Of the 7 eyes with residual lagophthalmos, 4 eyes exhibited improvement and only 3 showed no change.

Preoperative SPK was present in 49 of 50 eyes. The initial CEI did not differ significantly based on the severity of preoperative lid retraction present (Figure 5). The postoperative reduction in CEI was statistically significant for all three groups (severe, moderate, and mild all with  $P < .01$ ). There were no significant differences among the final CEI of the retraction severity groups.

Of the 32 patients undergoing upper eyelid blepharotomy, 14 (44%) had no measurable postoperative eyelid height asymmetry and 17 (53%) had asymmetry of  $\leq 1$  mm (Table III). Only 1 patient (3%) had asymmetry of  $>1.0$  mm, which was due to postoperative ptosis. Patients with mild severity of initial retraction in their highest eyelid had the least chance of having postoperative asymmetry. However, the amount of residual postoperative asymmetry was not statistically different among the retraction severity groups. Target final lid height of between 2 and 4 mm was achieved in 24 patients (75%) (Table IV) and 38 eyelids (76%) (Table II).

Postoperative upper lid crease recession  $>1$  mm was present in 10 (45%) of 22 patients for which data on final lid crease measurements were available. However, clinically significant, surgically induced lid crease height  $>10$  mm or induced lid crease asymmetry  $\geq 2$  mm occurred in only 4 patients (18%) in whom these measurements were made (Table V). Mild contour abnormalities were noted in 7 patients (22%). Contour abnormalities, occurring in 7 eyelids (14%) of 7 patients (Table V), were mild and less than 1 mm by comparing bilateral lid heights in corresponding sagittal planes. No patient noted any abnormality in lid crease height, although recession or asymmetry was induced in 4 (13%) of 32 patients.

No complications occurred during operations, which averaged  $31.5 \pm 8.9$  minutes per eyelid (range, 18 to 57 minutes). Postoperative complications included ptosis, overcorrection of lid contour requiring suture removal, wound dehiscence, and a full-thickness hole, which each occurred in one patient. No patient developed wound infection.

Intraoperative biopsy specimens from three previously unoperated eyelids in which irregular conjunctival/Müller muscle thickening was noted were stained with hematoxylin-eosin and Masson trichrome stains. All three biopsies demonstrated fibrosis of the conjunctival substantia propria as well as Müller's muscle.

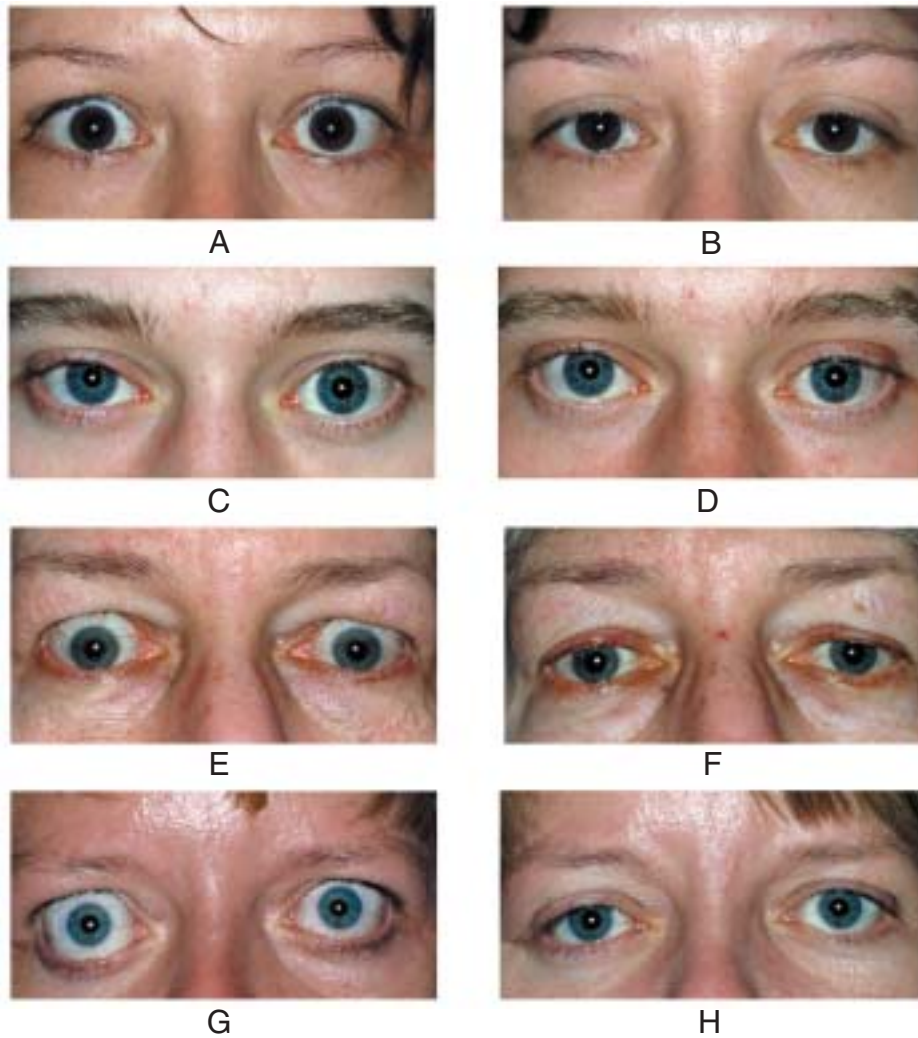

FIGURE I

Blepharotomy for GED-associated upper eyelid retraction. Before (A) and after (B) bilateral blepharotomies. Before (C) and after (D) unilateral blepharotomy. Before (E) and after (F) bilateral blepharotomies to obtain lower upper lid height for postradiation keratopathy. Before (G) and after (H) staged bilateral blepharotomies, the second stage consisting of medial blepharotomies

TABLE II: SEVERITY OF EYELID RETRACTION: EFFECT OF BLEPHAROTOMY IN 50 EYELIDS

DEGREE OF EYELID RETRACTION (LID HEIGHT)	NO. OF EYELIDS	PREOPERATIVE LID HEIGHT	POSTOPERATIVE LID HEIGHT	SIGNIFICANCE OF DIFFERENCE BETWEEN PREOPERATIVE AND POSTOPERATIVE LID HEIGHT	AMOUNT OF RECESSION (mm)	NO. OF EYELIDS WITH LID HEIGHT $\geq 2$ mm, $\leq 4$ mm
Severe ( $\geq 7.0$ )	15	$7.73 \pm 0.62 \pm 0.16$	$3.57 \pm 1.29 \pm 0.33$	$P < .00001$	$4.2 \pm 1.2 \pm 0.31$	8/15 (53%)
Moderate ( $>5.0$ to $<7.0$ )	21	$5.98 \pm 0.40 \pm 0.09$	$3.33 \pm 0.70 \pm 0.15$	$P < .00001$	$2.6 \pm 0.7 \pm 0.15$	17/21 (81%)
Mild ( $\leq 5.0$ )	14	$4.46 \pm 0.50 \pm 0.13$	$3.07 \pm 0.51 \pm 0.14$	$P < .00001$	$1.4 \pm 0.5 \pm 0.13$	13/14 (93%)

## DISCUSSION

GED inflammatory processes<sup>17</sup> diffusely affect orbital, eyelid, and facial tissues<sup>18-20</sup> and result in adipocyte proliferation, extracellular matrix deposition, and fibrosis within these tissues. Although upper eyelid retraction, the most

common clinical feature of GED,<sup>1</sup> is classified clinically as myogenic,<sup>3,21</sup> the pathogenesis of GED suggests that the retracted eyelid is diffusely affected by the disease.

Modifying the first proposed surgical methods<sup>22-24</sup> for the treatment of GED-associated upper eyelid retraction, Henderson,<sup>4</sup> in 1965, proposed a partial-thickness poste-

Graded Full-Thickness Anterior Blepharotomy for Upper Eyelid Retraction

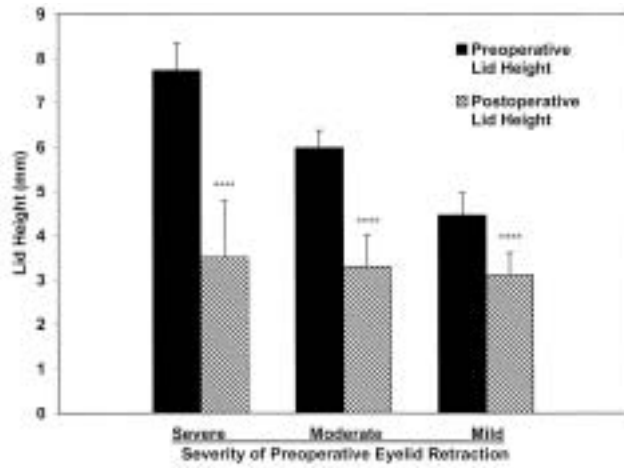


FIGURE 2

Effect of blepharotomy on upper eyelid height. Eyelids were divided into groups based on the severity of preoperative eyelid retraction: severe, lid height  $\geq 7$  mm; moderate, lid height,  $>5$  mm to  $<7$  mm; mild, lid height  $\leq 5$  mm. \*\*\*\* $P < .00001$ .

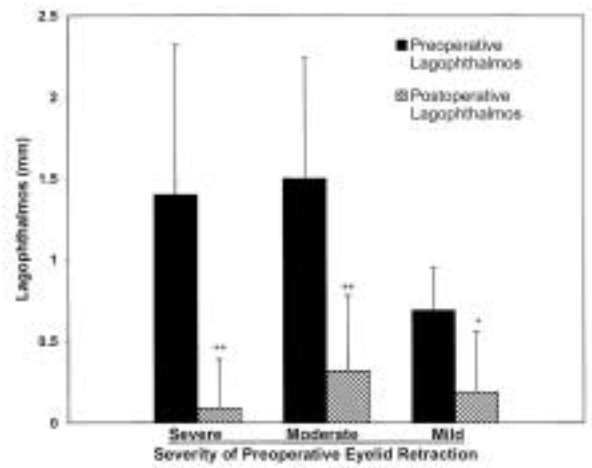


FIGURE 3

Effect of blepharotomy on lagophthalmos. Eyelids were divided into groups according to the severity of preoperative eyelid retraction as described in Figure 2. \*\* $P < .001$ ; \* $P < .01$ .

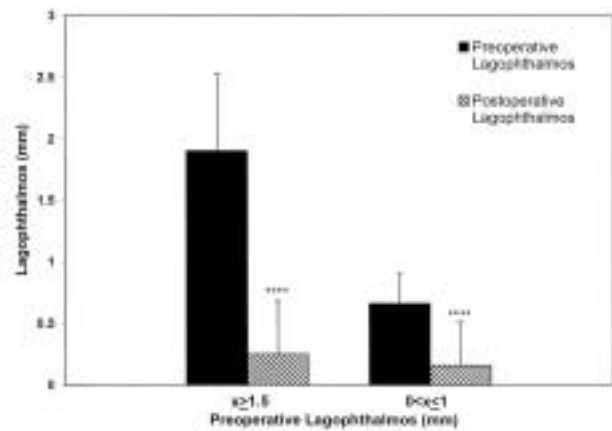


FIGURE 4

Reduction of lagophthalmos by blepharotomy. Preoperative lagophthalmos, x, was measured during gentle eyelid closure. \*\*\*\* $P < .00001$ .

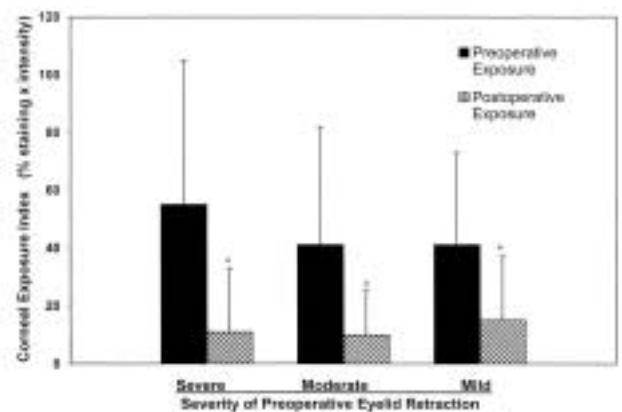


FIGURE 5

Effect of blepharotomy on corneal exposure. The corneal exposure index is the percentage of corneal surface with superficial punctate keratopathy (SPK) multiplied by the severity of SPK (0 to 4+). Eyelids were divided into groups according to the severity of preoperative eyelid retraction as described in Figure 2. \*\* $P < .01$ .

TABLE III: ASYMMETRY IN 32 PATIENTS AFTER FULL-THICKNESS BLEPHAROTOMY

DEGREE OF PREOPERATIVE RETRACTION IN HIGHEST EYELID	NO. OF PATIENTS	PATIENTS WITHOUT POSTOPERATIVE ASYMMETRY	PATIENTS WITH POSTOPERATIVE ASYMMETRY $\leq 1$ mm	PATIENTS WITH POSTOPERATIVE ASYMMETRY $> 1$ mm	AMOUNT (mm) IN PATIENTS WITH ASYMMETRY
Severe	11	2 (18%)	8 (73%) <sup>o</sup>	1 (9%)	$0.78 \pm 0.36 \pm 0.12$
Moderate	12	5 (42%)	7 (58%)	0	$0.57 \pm 0.19 \pm 0.07$
Mild	9	7 (78%)	2 (22%)	0	$0.75 \pm 0.35 \pm 0.25$
<b>Total</b>	<b>32</b>	<b>14 (44%)</b>	<b>17 (53%)</b>	<b>1 (3%)</b>	

TABLE IV: FINAL LID HEIGHT AFTER BLEPHAROTOMY IN 32 PATIENTS

DEGREE OF PREOPERATIVE RETRACTION IN HIGHEST EYELID	NO. OF PATIENTS	LID HEIGHT <2.0	LID HEIGHT ≥2.0 TO ≤4.0	LID HEIGHT ≥4.0 TO <5.0	LID HEIGHT ≥5.0
Severe	11	1 (9%)	5 (45%)	3 (27%)	2 (18%)
Moderate	12	0	10 (83%)	2 (17%)	0
Mild	9	0	9 (100%)	0	0
Total	32	1 (3%)	24 (75%)	5 (16%)	2 (6%)

TABLE V: EYELID CONTOUR AND CREASE IRREGULARITIES IN 32 PATIENTS

IRREGULARITY	NO. OF PATIENTS
Contour abnormalities	
Lateral peak	3
Central flattening	2
Medial ptosis	2
Induced lid crease recession*	
>10 mm height or ≥2 mm of asymmetry between sides	4

\*Data available on 22 of 32 patients.

rior blepharotomy approach. His method used a Müller muscle myotomy for mild or moderate retraction and additional graded division of the levator aponeurosis for severe retraction. While the technique was rapid and rarely overcorrecting, undercorrection and lateral temporal flare were common,<sup>25</sup> limiting its effective use to patients with mild retraction and limited temporal flare. Subsequently, numerous modifications of Henderson's technique have been proposed for the treatment of GED-associated upper eyelid retraction, but quantitative studies demonstrating consistent, reproducible, and graded recession to obtain desired lid height and symmetry are few.<sup>25,26</sup>

Furthermore, the plethora of proposed surgical methods is indicative of the highly variable results obtained with unpredictable final eyelid height and contour.<sup>25,27,28</sup> Most of these techniques utilize either (1) transconjunctival Müller's muscle myotomy/excision<sup>25</sup> or (2) transcutaneous levator aponeurotomy or myotomy with or without Müller's muscle myotomy/excision<sup>28</sup> with additional modifications, including levator transpositions/myoplasties, lid spacer grafts, and adjustable sutures.<sup>26</sup> None of the reported surgical methods utilize a full-thickness technique and do not address the diffuse nature of GED disease in the retracted eyelid, a contention supported by the conjunctival fibrosis we observed histopathologically in three cases. This shortcoming may be responsible for the highly variable results

reported to date for surgical correction of GED-associated upper eyelid retraction.

Our results indicate that the Koornneef full-thickness anterior blepharotomy permits graded recession of the retracted upper eyelid to achieve consistent final lid height (Table II; Figure 2) and contour (Table V), regardless of the severity of preoperative eyelid retraction. The highly accurate, graded ameliorative effect of the blepharotomy technique is evidenced by comparison of postoperative eyelid heights, which were not statistically different regardless of initial retraction severity (Table II). Lateral temporal flare is easily addressed when the lateral horn is cut through an anterior approach (Figure 1C, 1D), while medial overcorrection causing ptosis and contour deformity is rare. In our study, postoperative central flattening is avoided by either (1) placing a dissolvable suture at the apex of the lid arch or (2) performing a later, separate full-thickness blepharotomy to address medial retraction in a staged fashion, as we did in two patients with severe retraction (Figure 1G, 1H).

The effectiveness of the full-thickness blepharotomy technique is reflected in the fact that 93% of preoperative symptoms were resolved or improved by the surgery (Table I). The ameliorative effects of the blepharotomy on symptoms were accompanied by complete resolution of lagophthalmos in 77% of eyes and reduction of exposure keratopathy by an average of 75%. Cosmetically, all patients, except for one whose results were complicated by ptosis, had resolution of symptomatic asymmetry (Table I). The postoperative contour abnormalities present in 7 eyelids (14%) (Table V), were all unilateral, mild, and asymptomatic. Likewise, no patient complained of any abnormality in lid crease height or asymmetry.

Limited dissection and short operative time reduce postoperative morbidity and complications, inasmuch as dissection is directly posterior, limiting superior and inferior disruption of multiple tissue planes. Some of the advantages of the technique include preservation of (1) levator aponeurosis fibers forming the lid crease, (2) the orbital septum and fat pads, (3) levator aponeurosis/Müller muscle/conjunctival complex in the superior portion of the eyelid, and (4) support of the

superior conjunctival fornix. Maintenance of these relationships reduces iatrogenic lid deformities and spread of hemorrhage and edema into these structures. In evaluating Henderson's technique, Olver and Fells<sup>25</sup> proposed that leaving the conjunctiva unsutured leads to conjunctival shortening and recurrence of lid retraction. Our results, however, show that dissection through the conjunctiva is an essential part of the surgical correction, since GED-induced fibrosis involves the conjunctival substantia propria. Thus, conjunctival release improves outcomes. It also allows blood drainage from the surgical site, thereby preventing lid height and contour abnormalities due to the weight of accumulated hematoma and edema fluid.

This simple, rapid method does not require implantation of foreign material or permanent sutures. Postoperatively, no taping or traction suture is necessary. Furthermore, the technique may be performed with excellent results (data not shown) on eyelids that have failed previous attempts at recession or are retracted because of overcorrected ptosis or trauma.

Koornneef's graded full-thickness anterior blepharotomy technique targets the functional and cosmetic needs of patients with GED-associated upper eyelid retraction, regardless of severity. This technique effectively treats the signs and symptoms of exposure keratopathy and lagophthalmos while obtaining excellent cosmetic results.

## REFERENCES

- Bartley GB. The epidemiologic characteristics and clinical course of ophthalmopathy associated with autoimmune thyroid disease in Olmsted County, Minnesota. *Trans Am Ophthalmol Soc* 1994;92:477-588.
- Frueh BR, Musch DC, Garber FW. Lid retraction and levator aponeurosis defects in Graves' eye disease. *Ophthalmic Surg* 1986;17:216-220.
- Chang EL, Rubin PAD. Upper and lower eyelid retraction. *Int Ophthalmol Clin* 2002;42:45-59.
- Henderson JW. A surgical procedure for retraction of eyelids in endocrine exophthalmos: a moving picture. *Trans Am Ophthalmol Soc* 1965;63:70-74.
- Putterman AM, Fett DR. Mueller's muscle in the treatment of upper eyelid retraction: a 12-year study. *Ophthalmic Surg* 1986;17:361-367.
- Harvey JT, Anderson RL. The aponeurotic approach to eyelid retraction. *Ophthalmology* 1981;88:513-524.
- Baylis HI, Cies WA, Kamin DF. Correction of upper eyelid retraction. *Am J Ophthalmol* 1976;82:790-794.
- Callahan A. Levator recession: with reattachment to the tarsus with collagen film. *Arch Ophthalmol* 1965;73:800-802.
- Putterman AM, Urist MJ. A simplified levator palpebrae superioris muscle recession to treat overcorrected blepharoptosis. *Am J Ophthalmol* 1974;77:358-366.
- Collin JR, O'Donnel BA. Adjustable sutures in eyelid surgery for ptosis and lid retraction. *Br J Ophthalmol* 1994;78:167-174.
- Grove AS. Eyelid retraction treated by levator marginal myotomy. *Ophthalmology* 1980;87:1013-1018.
- Doxanas MT, Dryden RM. The use of sclera in the treatment of dysthyroid eyelid retraction. *Ophthalmology* 1981;88:887-894.
- Downes RN, Jordan K. The surgical management of dysthyroid related eyelid retraction using mersiline mesh. *Eye* 1989;3:385-390.
- Mourits MP, Koornneef L. Lid lengthening by sclera interposition for eyelid retraction in Graves' ophthalmopathy. *Br J Ophthalmol* 1991;75:344-347.
- Henderson JW. Relief of eyelid retraction: a surgical procedure. *Arch Ophthalmol* 1965;74:205-216.
- Fante RC, Elnor VM. The use of epinephrine in infiltrative local anesthesia for eyelid reconstruction. *Plast Reconstr Surg* 1999;102(3):917.
- Bahn RS, Heufelder AE. Pathogenesis of Graves' ophthalmopathy. *N Engl J Med* 1993;329:1468-1475.
- Clauser L, Galie M, Sarti E, et al. Rationale of treatment in Graves ophthalmopathy. *Plast Reconstr Surg* 2001;108:1880-1894.
- Goldberger S, Sarraf D, Bernstein JM, et al. Involvement of eyebrow fat pad in Graves' orbitopathy. *Ophthalm Plast Reconstr Surg* 1994;10:80-86.
- Small RG. Upper eyelid retraction in Graves' ophthalmopathy: a new surgical technique and a study of the abnormal levator muscle. *Trans Am Ophthalmol Soc* 1988;86:725-793.
- Bartley GB. The differential diagnosis and classification of eyelid retraction. *Ophthalmology* 1996;103:371-389.
- Goldstein I. Recession of the levator muscle for lagophthalmos in exophthalmic goiter. *Arch Ophthalmol* 1934;11:389-393.
- Moran RE. The correction of exophthalmos and levator spasm. *Plast Reconstr Surg* 1956;18:411-426.
- von Blaskovics L, Kettesy A. *Eingriffe am Auge: eine Anleitung zur operativen Tätigkeit des Augenarztes*. 2nd ed. Stuttgart, Germany: Ferdinand Enk, 1945:37-39.
- Olver JM, Fells P. Henderson's relief of eyelid retraction revisited. *Eye* 1995;9:467-471.
- Lai S-S, Lin T-M, Tsai C-C, et al. A new technique for levator lengthening to treat upper eyelid retraction: the orbital septal flap. *Aesthetic Plast Surg* 2002;26:31-34.
- Ceisler EJ, Bilyk JR, Rubin PAD, et al. Results of mullerotomy and levator aponeurosis transposition for the correction of upper eyelid retraction in Graves disease. *Ophthalmology* 1995;102:483-492.
- Piggot TA, Niazi ZBM, Hodgkinson PD. New technique of levator lengthening for the retracted upper eyelid. *Br J Plast Surg* 1995;48:127-131.

## DISCUSSION

DR GEORGE B. BARTLEY. The repair of upper eyelid retraction can be accomplished either transcutaneously or

transconjunctivally. The anterior approach through the skin has the advantage of being more anatomically familiar for most surgeons. The posterior route was the method favored by my teacher and colleague, Dr Robert Waller, whose AOS thesis<sup>1</sup> was a seminal contribution to oculoplastic surgery. One plus of approaching the eyelid retractors through the conjunctiva is a shorter operative time. Additionally, after using both approaches for many years, I've concluded that there are a few recalcitrant eyelids that simply will not "say Uncle" until the conjunctiva has been released.

What do cases that require a full-thickness blepharotomy teach us about the pathophysiology of eyelid retraction? Suspecting that something must be amiss in the palpebral conjunctiva, about a decade ago I asked Dr Jean Campbell to examine tissue from a few patients whose retracted eyelids would not "drop" until all layers of the eyelid had been transected. The conjunctival ultrastructure, disappointingly, appeared unremarkable. It is notable that in this study Dr Elnier and colleagues identified fibrosis in the substantia propria.

I shared a few trivial suggestions about this paper with the authors in early April and they are as follows:

1. Postoperative follow-up was less than 6 months for an unspecified number of patients. The authors mentioned that there was no difference in final eyelid height between patients with 6 months or more of follow-up versus those with 2-6 months, but it would be more relevant to demonstrate that the eyelid position at, say, 8 months was the same as the position 2 months after surgery. Dr Elnier mentioned to me that this point has been addressed in the updated version of the manuscript.
2. The reference point for eyelid height was "the center of the pupil." It was unclear whether this was the same as the corneal light reflex, which for some practitioners is a more accurate landmark.
3. The lack of an association between the corneal exposure index and the severity of preoperative upper eyelid retraction may not mean much if the presence of lower eyelid retraction (which was present in at least one of the patients whose photographs were included with the manuscript) was not considered.
4. Although 93% of symptoms improved after surgery, only about 75% of patients had a final eyelid height (above the pupil) of 2 mm and 4 mm. This overall functional and anatomic success rate is similar to my experience.

## REFERENCES

1. Waller RR. Eyelid malpositions in Graves' ophthalmopathy. *Trans Am Ophthalmol Soc* 1982;80:855-930.

DR ARTHUR JAMPOLSKY. All or a significant part of the retraction may be due to contracture of the inferior rectus muscles. It's always nice to see the rotations in down-gaze. If there is no retraction in down-gaze then all of the retraction in the primary position may be ameliorated by recession of the inferior rectus muscles. So it depends on the degree of inferior rectus involvement.

If the lid alone is operated upon without knowing that relationship and if the inferior rectus muscles develop more contractures to cause hyper deviations in right and left gaze and also in the primary position, then recessing the inferior rectus muscles, which are necessary for these deviations alone, will overcorrect the previously performed blepharoplasty.

DR ALAN H. FRIEDMAN. Did any of the patients have preoperative radiotherapy and, if so, did that contribute to any of the preoperative symptoms or did that affect the postoperative results?

DR VICTOR M. ELNER. In regard to our follow-up on these patients, 13 of them were initially in the 2 to 6 month category, most of them were at 4 or 5 months, and many of them have been subsequently evaluated. We measure from the midpupil to the upper eyelid margin because that is what we do in the operating room. Another reason is the theoretical elimination of the possibility of an angle kappa that may obfuscate the measurements.

The corneal exposure index may not correlate with the severity of retraction since patients come to us with a variety of symptoms and treatment expectations. On the one hand, some patients have dry eyes and/or meibomian gland dysfunction. Thus, one patient may become symptomatic with exposure keratopathy and a lid height that might not cause another patient to manifest exposure symptoms and signs. On the other hand, we have some patients with significant cosmetic concerns and lesser degrees of keratopathy, which is why the target for lid retraction surgery differs in various patients. Individuals with drier eyes usually present when their lid retraction is mild or moderate. Patients with good ocular wetting may not present until their symptoms are severe, but desire correction to improve appearance while maintaining a higher lid height. This is also a reason for lack of correlation between severity of lid retraction and keratopathy. As was alluded to by Dr. Friedman, some of these patients did have radiotherapy that made their eye drier; they required more substantial lowering of the lid. This contrasts with younger patients for which we had a higher target, leaving only 1 mm of leeway for error in their recession, if failure is designated at 5 mm.

Some patients did have lower eyelids retraction, which required treatment, but the corneal exposure index

was assessed before and after upper eyelid recession and not confounded by concurrent lower eyelid correction.

Insofar as inferior rectus contraction is concerned, none of our patients had any type of muscle surgery; some of these patients had decompression and then lid surgery. We did not note strabismus or overaction of the levator muscle due to inferior rectus restriction in any of them. In all patients, their ocular axis was parallel to the ground in primary gaze and the lids were retracted on downgaze. We believe that these patients truly had retraction due to upper eyelid contracture; their eyelid positions were stable after the surgery during the follow-up period.

